

ACQUISITION GRADIENT-ECHO VERSUS MAGNETIC RESONANCE VENOGRAPHY
IN THE EVALUATION OF DURAL VENOUS SINUSESDr. Maryam Khalil Abduljaleel Aldoosari*¹, Prof. Dr. Mohammed Abd Kadhim²¹M. B. Ch. B., ²M. B. Ch. B., F. I. B. M. S.Professor in Diagnostic Radiology/Iraqi Board of Medical Specialization, Medical College/Al-Nahrain University
Consultant Radiologist, Al-Imamain Al-Kadhmain Medical City.

Article Received: 05 March 2026

Article Revised: 25 April 2026

Article Published: 04 April 2026



*Corresponding Author: Dr. Maryam Khalil Abduljaleel Aldoosari

M. B. Ch. B., Professor in Diagnostic Radiology/Iraqi Board of Medical Specialization, Medical College/Al-Nahrain University Consultant Radiologist, Al-Imamain Al-Kadhmain Medical City.

DOI: <https://doi.org/10.5281/zenodo.19436372>**How to cite this Article:** Dr. Maryam Khalil Abduljaleel Aldoosari*¹, Prof. Dr. Mohammed Abd Kadhim² (2026). Acquisition Gradient-Echo Versus Magnetic Resonance Venography in the Evaluation of Dural Venous Sinuses. World Journal of Advance Healthcare Research, 10(4), 303–314.

This work is licensed under Creative Commons Attribution 4.0 International license.

ABSTRACT

Background: The dural venous sinuses are a network of venous channels located within the dura mater. Disorders of these sinuses can lead to serious consequences. Recent studies indicate that dural venous sinus disorders are more common than previously thought, due to significant advancements in magnetic resonance imaging and high-resolution computed tomography scans. **Aims:** To assess the value of contrast enhanced Magnetization prepared rapid acquisition gradient-echo versus magnetic resonance venography in the evaluation of dural venous sinuses.

Methods: This is a cross-sectional study. It was conducted at the Department of Radiology Baghdad teaching hospital, Medical City complex and Al Imamain Al Khadhmain medical city from February 1, 2025, to December 30, 2025. 193 patients enrolled in this study. The images were independently reviewed by two experienced radiologists blinded to clinical data and imaging results. The presence of normal venous anatomy or if there are anatomical variants and clinically significant pathology were documented. The final diagnosis was based on a composite reference standard that included; interpretation of all magnetic resonance imaging sequences with clinical presentation of the patients. **Results:** The mean age of the study participants was 43.35 ± 17.41 years and the patients age was ranged from 26-65 years. Of the included patients, 125 were female and 68 were male, yielding a female-to-male ratio of 1.838:1. There was significant inter-observer agreement for the assessment of normal venous anatomy, anatomical variants, and pathological findings. In addition, the two imaging sequences demonstrated significant agreement for normal findings and moderate agreement for both anatomical variants and pathological findings. A statistically significant difference was observed between MPRAGE and MRV with respect to image quality ($P = 0.011$) and image clarity ($P < 0.001$). Furthermore, contrast enhanced Magnetization prepared rapid acquisition gradient-echo showed superior diagnostic performance compared with magnetic resonance venography in differentiating normal venous anatomy from normal anatomical variants, pathological findings, and normal anatomical variants from pathological conditions, as well as in distinguishing acute from chronic venous sinus thrombosis. **Conclusions:** Contrast enhanced Magnetization Prepared Rapid Acquisition Gradient Echo had superior sensitivity, specificity, positive predictive value, negative predictive value and accuracy than magnetic resonance venography in showing normal venous architectural, normal anatomical variants and diagnosing dural venous disorders. However, the final diagnosis is depended on combination of these sequences.

KEYWORDS: Brain, Diagnostic, Disorder, Dura, Neuroimaging, Vein.

1-INTRODUCTION

The dural venous sinuses are a network of venous channels present within the dura mater.^[1] Disorders of the dural venous sinuses can have severe consequences. These include dural venous sinus thrombosis (DVST), which can be caused by head trauma, chronic or acute illnesses, or hormonal factors.^[2] Blockage can raise intracranial pressure, resulting in symptoms such as headache and vision problems. Infections can move to the sinuses via emissary veins, and traumatic brain injury can induce sinus damage and bleeding due to their complicated anatomy.^[3-4] Dural sinus thrombosis is a clinical and radiological emergency that requires special attention and a high index of suspicion. As early identification and treatment of sinus thrombosis can significantly improve prognosis and reduce morbidity and mortality.^[3] Proper diagnosis and therapy necessitate collaboration between the treating physician and radiologist. However, in some circumstances, the radiologist should be familiar with the common radiological signs associated with sinus disorders and variants in standard MRI sequences before confirming with specific sequences.^[4]

Congenital anomalies of the dural venous sinus are birth-related abnormalities such as dural sinus ectasia (widening of the sinus itself), or dural sinus malformation (DSM) such as developmental venous anomaly (DVA), vein of Galen aneurysmal malformations (VGAMs) and arteriovenous malformations (AVM).^[5]

Although some cases may resolve spontaneously, it can cause serious complications like thrombosis, elevated intracranial pressure, cardiac failure and even death or long-term neurological deficit.^[6]

In the early stages of dural venous sinus thrombosis (DVST), conventional MRI is often insensitive to secondary changes such as venous infarction or dilated collateral cortical/medullary veins.^[7] Diagnosing sinus thrombosis might be challenging due to overlapping signal intensities caused by the thrombus temporal evolution.^[7] Two-dimensional time-of-flight (2D-TOF) MR venography, CT venography are frequently used to detect dural sinus thrombosis although digital subtraction angiography (DSA) was the gold standard imaging modality for detection of dural venous sinuses pathologies, nowadays becoming less popular as it is considered invasive procedure.^[7] 2D-TOF MR venography may fail to differentiate between hypoplastic or atretic sinuses and thrombosis, also has the limitation of vascular signal loss, which occurs when the direction of blood flow is inside the imaging plane.^[8]

Contrast enhanced CT-venography has been comparable to MR venography (2D TOF); nevertheless, use of iodinated contrast material, radiation exposure and substantial postprocessing is required. Furthermore, the

poor characterization of skull base structures and post processing restricts its usage.^[9]

DSA was the gold standard for diagnosing dural sinus patency and thrombosis, even though it is invasive.^[10] Thus, a less invasive, more accurate, and more effective diagnostic method is needed. Magnetization prepared rapid gradient-echo (MPRAGE), a recently developed sequence, has been reported to provide strong contrast between sinuses and surrounding structures, as well as to properly characterize venous systems by contrast enhanced MPRAGE.^[7]

2-PATIENTS AND METHODS

This is a cross-sectional study. The study data was taken from the Department of Radiology Baghdad teaching hospital, Medical City complex and Al Imamain Al Khadhmain medical city, during the period from 1st of February 2025 to the end of December 2025.

Patients with suspicion of dural venous sinus pathology (depending on clinical and/or conventional MRI sequences) such as cerebral venous sinus thrombosis, dural venous sinus stenosis, equivocal venous sinus abnormality or normal variant were included in the study. On the other hand, the study excluded patients with non diagnostic or poor image quality MRI, patients with contraindications to gadolinium-based contrast agents, patients who were unable to do both sequences in same session, patients with head and neck conditions affecting venous drainage, those patients with systemic condition affect the venous flow, such as severe dehydration and septic shock or patients who had previous Gamma knife irradiation and patients with primary or secondary central nervous system tumor.

The information was collected by specifically designed data collecting form including the date of examination, patient's identification number, age, gender and smoking state. In addition to patients suspected clinical diagnosis such as venous cavernous sinus thrombosis, headache evaluation, intracranial hypertension and papilledema. Moreover, duration of symptoms was documented (less than 24 hours, 1-7 days, 1-4 weeks and more than 4 weeks). Furthermore, patient's relevant history was reported, including; hypertension, diabetes mellitus, kidney, liver and heart diseases relevant to the patient condition. Additionally, the presence of previous stroke, blood clotting disorders, anemia, autoimmune disease, migraine, previous cancer, venous thrombosis, recent surgery (other than surgical intervention that affect dural venous sinuses anatomy), postpartum period and recent infection. The collecting form also included patient drug history for example anticoagulant, contraceptive pills or hormonal replacement treatment, steroid and chemotherapy. Furthermore, patient ability for lying flat was also recorded to exclude those with motion artifact. After taking brief history and signing informed consent, the patient was sent for serum creatinine and blood urea tests. Right intravenous antecubital vein access with an

18-22 gauge cannula was obtained for contrast infusion (rate of 1.5 to 2 mL/s). Additionally, prior to MRI, all patients were given standardized instructions. Patients were checked for MRI contraindications. Patients were told to remove all metallic objects such as jewelry, watches, hairpins, dentures, and hearing aids. Hospital gowns were available if necessary. The patients were instructed to stay as motionless as possible during the examination and breathe as slowly as possible to reduce motion artifacts. Patients were warned that the scanner makes loud noises and were given ear protection.

Conventional MRI/ MRV was done at first, after that gadolinium-based contrast agent was injected at a dose of 0.1 mmol/kg body weight and saline was used for flushing after it. MPRAGE sequence exam begins post contrast (3-5 minutes). The total MRI examination was usually lasted for 10-15 minutes by using 1.5 T Achieva MRI unit (Philips medical system, Netherlands) with 16-channel sensitivity-encoding head coil in supine position. The head is comfortably positioned in a specialized head coil. The images were independently reviewed by two experienced radiologists blinded to clinical data and imaging results. The presence of normal venous anatomy or if there are anatomical variants (for example, hypoplasia, asymmetry, arachnoid granulation) and clinically significant pathology were documented. Discrepancies were resolved by consensus. The final diagnosis was based on a composite reference standard

that included; interpretation of all MRI sequences with clinical presentation of the patients.

Data were analyzed using statistical software SPSS (IBM Statistical Package for social Science version 30). Continuous data were expressed as mean \pm standard deviation, whereas categorical variables were expressed as frequencies and percentages. Categorical variables were compared using the Chi-square test or Fisher's exact test, if applicable. An independent student t-test was used to compare continuous variables. McNemar's test was used for comparing accuracy measurements. A P value < 0.05 indicated statistical significance. The diagnostic performance of contrast enhanced MPRAGE and MRV sequences was assessed using sensitivity, specificity, positive predictive value (PPV), negative predictive value (NPV), and overall accuracy, with the final diagnosis serving as the reference standard. The inter-observer agreement was evaluated using Cohen's kappa (κ) coefficient. The level of agreement was categorized as poor (<0.20), fair (0.21-0.40), moderate (0.41-0.60), significant (0.61-0.80), and perfect (>0.80). Concordance of both sequence diagnosis was calculated as the proportion of instances with identical findings between the two sequences in normal anatomical findings, as well as for normal variants and pathological findings.

3- RESULTS

The study includes 193 patients. Of them 125 patients were females and 68 were males with female to male ratio of 1.838:1. The mean age \pm standard deviation of the study participants was 43.35 ± 17.41 years and the patients age was range from 26-65 years. The majority of patients were non-smokers, presented with headache alone and symptoms duration of 1-4 weeks. As shown in figure 3.1, figure 3.2, figure 3.3 and figure 3.4.

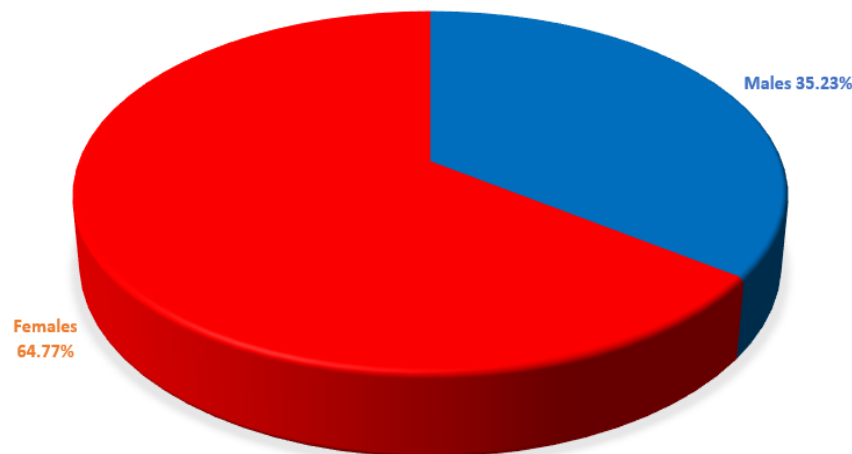


Figure 3.1: Distribution of the study participants according to their gender.

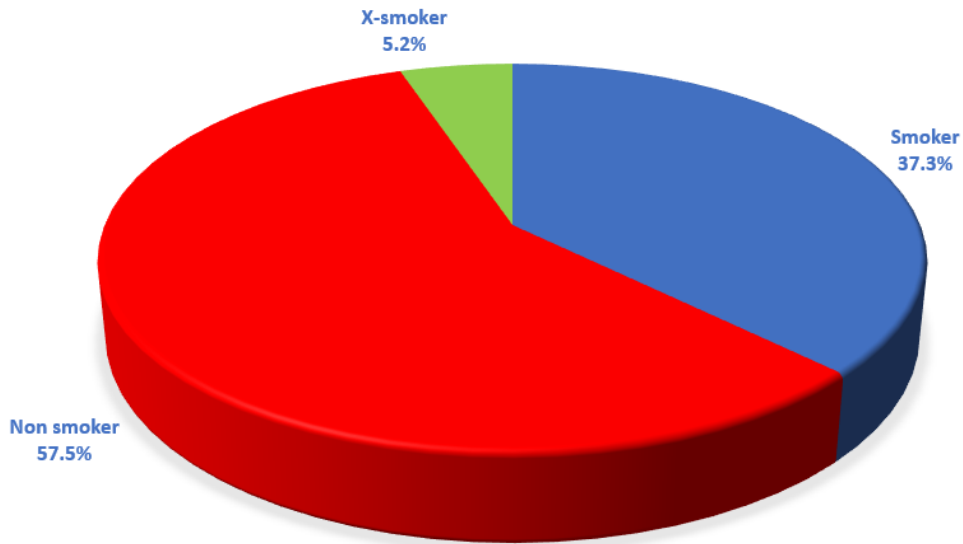


Figure 3.2: Distribution of the study participants according to their smoking state.

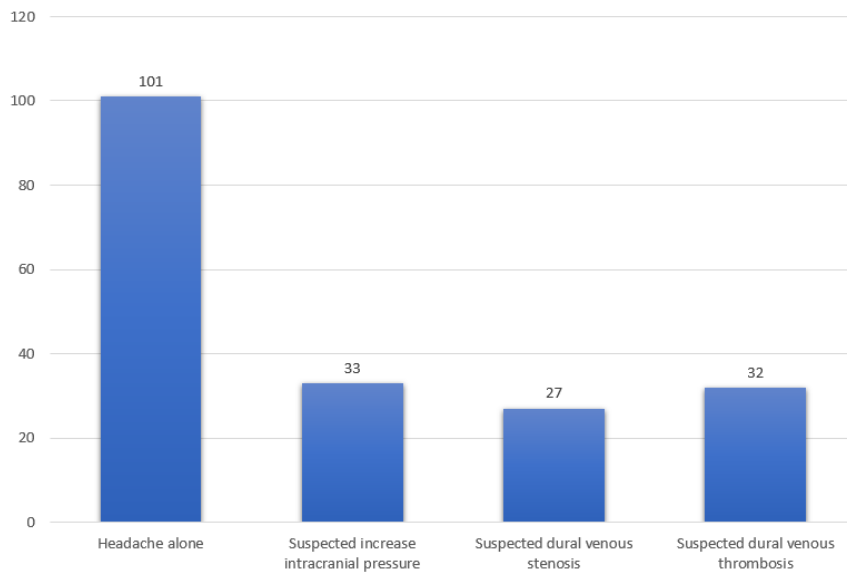


Figure 3.3: Distribution of the study participants according to their cause of referral.

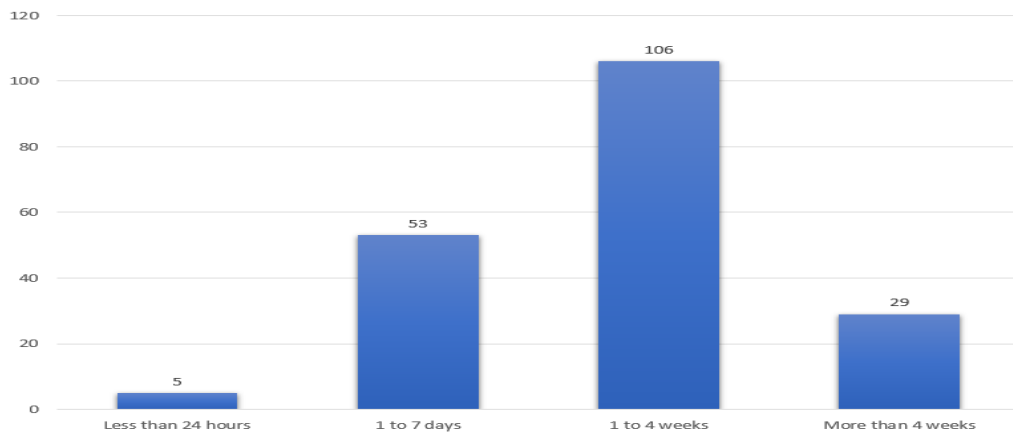


Figure 3.4: Distribution of the study participants according to their headache duration.

Table 3.1 shows description of patients past medical comorbidities. It's evident that 66 (34.19%) participants reported no past history while 127 (65.80%) participants reported various medical comorbidities. Of note, many

participants report more than one comorbidity at the same time.

Table 3.1: Patients' comorbidities of the study patients (number = 193).

Variable	Number = 193	Percent
Medical comorbidities		
-None	66	34.19%
-Hypertension	48	24.87%
- Diabetes mellitus	55	28.49%
-Migraine	64	33.16%
-Anemia	22	11.39%
-Multiple sclerosis	10	5.18%
-Previous stroke	8	4.14%
-Postpartum period	9	4.66%
-Recent tuberculosis	3	1.55%
-Blood clotting disorder	2	1.03%
-Systemic lupus erythematosus	1	0.51%
-Recent surgery other than brain surgery	23	11.91%

Table 3.2 summarizes the findings from each sequence and the final diagnosis according to the radiologists' agreement. In comparison to the final diagnosis, MPRAGE showed 91 patients with normal findings (true negative), while 4 patients had normal anatomical variants but MPRAGE diagnosed as normal (false negative). Furthermore, MPRAGE diagnosed 1 patient with acute venous thrombosis but the final diagnosis was normal anatomical variant (false positive), while 97 patients were truly diagnosed (true positive). On the

other hand, MRV diagnosed 81 patients with normal brain anatomy (true negative), while MRV showed 16 patients were falsely diagnosed (false positive), in other word, 10 of them were diagnosed as normal anatomical variant but the final diagnosis was normal and 6 of them were diagnosed as normal anatomical variant but the final diagnosis was either acute venous thrombosis (in 4 patients), chronic venous thrombosis (1 patient) and dural venous sinus stenosis (1 patient). Additionally, 96 patients were truly diagnosed (true positive).

Table 3.2: The study main findings (number = 193).

Variable	MPRAGE	MRV	Final diagnosis according to the radiologists' agreement
Normal anatomy, number (%)	95 (49.22%)	81 (42.22%)	91 (47.15%)
Normal anatomical variant, number (%)			
- Hypoplastic sinus	33 (17.10%)	45 (23.31%)	35 (18.13%)
- Aplastic sinus	9 (4.66%)	13 (6.73%)	10 (5.18%)
- Arachnoid granulation	24 (12.43%)	29 (15.03%)	26 (13.48%)
Pathological findings			
- Acute venous thrombosis	15 (7.78%)	10 (5.18%)	14 (7.25%)
- Chronic venous thrombosis	9 (4.66%)	8 (4.15%)	9 (4.66%)
- Dural venous sinus stenosis	8 (4.15%)	7 (3.62%)	8 (4.15%)
Total, number (%)	193 (100%)	193 (100%)	193 (100%)

Table 3.3 shows inter-observer agreement, contrast enhanced MPRAGE versus MRV agreement and concordance. Significant inter-observer agreement was found for all of normal, anatomical variants and pathological findings. Furthermore, both sequences were in significant agreement for normal findings and in moderate agreement for normal variants and pathological findings. Discrepancies occurred in a small number of patients, mostly due to MRV misclassifying certain

normal sinuses as variants or classify variants as pathological findings due mild flow-related artifacts (figure 3.5, figure 3.6 and figure 3.7). On the other hand, the concordance for normal findings was occurred in (70.9%) of instance, while for normal anatomical variants the concordance was (54.2%) and (25%) for pathological findings.

Table 3.3: Inter-observer agreement, MPRAGE versus MRV agreement and concordance (number = 193).

Variable	Results
Inter observer agreement, Cohen’s (κ):	
-Normal anatomical agreement	0.7024
-Agreement for normal variant findings	0.6528
-Agreement for pathological findings	0.6869
MPRAGE and MRV agreement, Cohen’s (κ):	
-Normal anatomy agreement	0.6839
-Agreement for normal variant findings	0.5489
-Agreement for pathological findings	0.4728
MPRAGE and MRV concordance:	
-Concordance for normal anatomy	70.9%
-Concordance for normal variant findings	54.2%
-Concordance for pathological findings	25%

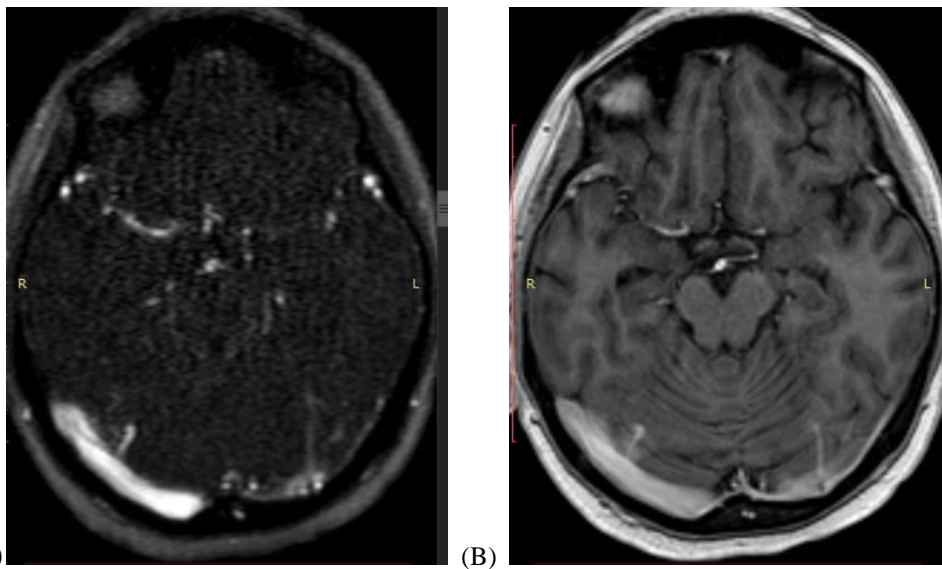


Figure 3.5: 39 years old female on oral contraceptive pills develops chronic headache, the study was reviewed by conventional MRI sequences and by the image (A) MRV showing stenotic left transverse sinus with irregular filling defect at its proximal half suspecting old transverse sinus thrombosis with partial recanalization. (B) Contrast enhanced MPRAGE showing patent hypoplastic transverse sinus with nodular intraluminal filling defect appears to be arachnoid granulation.

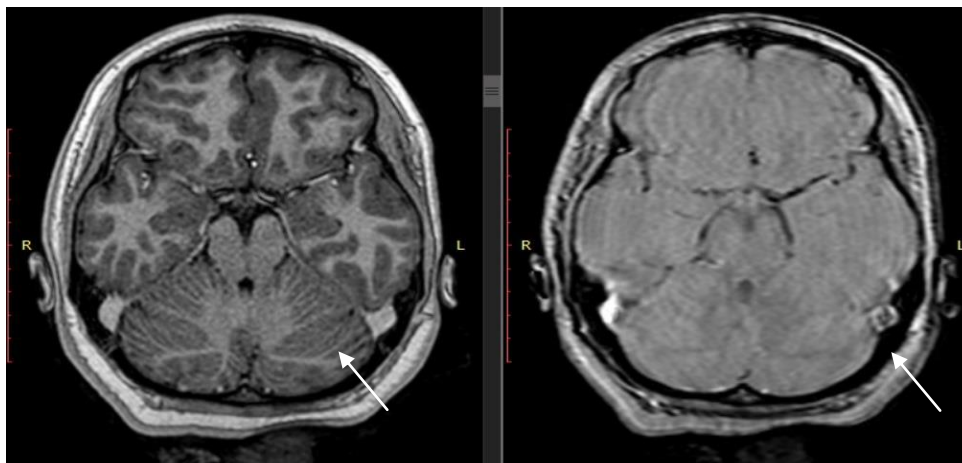


Figure 3.6: 43 years old male heavy smoker with elevated PCV develops headache for 3 weeks duration, Comparative image of MPRAGE and MRV, investigating filling defect on MRV, contrast study administration was done and showing symmetrical transverse sinus diameter bilaterally, filling defect noticed in MRV at left sigmoid sinus, reviewing the MPRAGE classify the left sigmoid as normal sinus and this filling defect was flow related artifact (arrows).

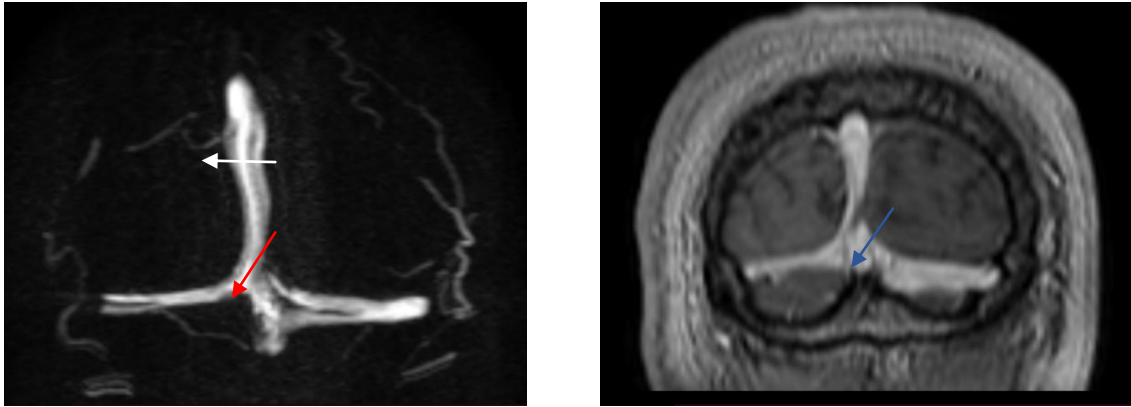


Figure 3.7: 29 years old postpartum female MRV coronal source image showing multiple linear filling defects especially the left transverse sinus was confused as acute thrombosis VS flow artifacts (red arrow). Final diagnosis was normal sinuses and the aforementioned filling defects considered intraluminal inhomogeneous signal by MPRAGE (blue arrow).

Table 3.4 shows comparison between the two sequences regarding their image quality judged by the reporting radiologists. Statistically significant

difference found (P value = 0.011) between them regarding this topic (contrast enhanced MPRAGE sequence showing higher excellent image quality).

Table 3.4: Image quality of the study patients (number = 193).

Image quality	MPRAGE		MRV		P value
	Number	Percent	Number	Percent	
-Excellent	191	98.96%	182	94.30%	0.011
-Acceptable	2	1.04%	11	5.70%	

Table 3.5 shows comparison between the two sequences regarding their clarity as judged by the reporting radiologists. Statistically significant difference between MPRAGE and MRV (P value <0.001) with contrast

enhanced MPRAGE sequence showing clearer images in 51 (26.42%) patients versus only 5 (2.60%) patients MRV showed clearer sequence.

Table 3.5: Image clarity of the study patients (number = 193).

Clearer sequence	Number	Percent
-Both equal	137	70.98%
- Contrast enhanced	51	26.42%
-MRV	5	2.60
P value		<0.001

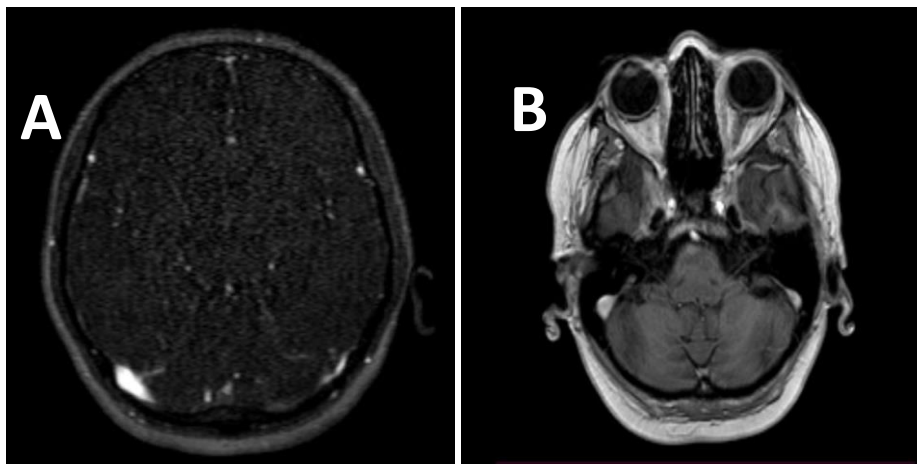


Figure 3.8: 55 years old hypertensive and diabetic female presented with headache for 4 weeks. (A) MRV source axial image showing left transverse sinus, ipsilateral sigmoid sinus and left internal jugular vein are not clearly visualized. Other dural venous sinuses are within normal limits. (B) post contrast sequence showing hypoplastic left transverse sinus with the sigmoid sinus and jugular vein on same side are completely patent but relatively smaller in diameter in comparison to other side.

Table 3.6 shows comparison between the two sequences regarding their accuracy measurements in differentiation normal from pathological findings. Statistically significant difference between the two

sequences regarding their sensitivity, specificity, positive predictive value, negative predictive value and accuracy of the test (P value <0.001).

Table 3.6: Comparison between the two sequences regarding their accuracy measurements in differentiation normal from pathological findings.

Variable	CE-MPRAGE	MRV	P value
Sensitivity	95%	77.9%	<0.001
Specificity	91.4%	83.0%	<0.001
Positive predictive value	92.2%	84.2%	<0.001
Negative predictive value	94.4%	77.3%	<0.001
Accuracy of the test	93.3%	84.5%	<0.001

Table 3.7 shows comparison between the two sequences regarding their accuracy measurements in differentiation normal from normal anatomical variants. Statistically significant difference between the two sequences regarding their sensitivity,

specificity, positive predictive value, negative predictive value and accuracy of the test (P value <0.001).

Table 3.7: Comparison between the two sequences regarding their accuracy measurements in differentiation normal from anatomical variants.

Variable	CE-MPRAGE	MRV	P value
Sensitivity	92.8%	82.9%	<0.001
Specificity	91.4%	84.8%	<0.001
Positive predictive value	88.9%	80.6%	<0.001
Negative predictive value	94.4%	86.7%	<0.001
Accuracy of the test	91.4%	84.0%	<0.001

Table 3.8 shows comparison between the two sequences regarding their accuracy measurements in differentiation normal anatomical variants from pathological findings. Statistically significant difference between the two

sequences regarding their sensitivity, specificity, positive predictive value, negative predictive value and accuracy of the test (P value <0.001).

Table 3.8: Comparison between the two sequences regarding their accuracy measurements in differentiation normal anatomical variants from pathological findings.

Variable	CE-MPRAGE	MRV	P value
Sensitivity	80.6%	58.1%	<0.001
Specificity	93.1%	86.1%	<0.001
Positive predictive value	83.3%	64.3%	<0.001
Negative predictive value	91.8%	82.0%	<0.001
Accuracy of the test	88.3%	77.7%	<0.001

Table 3.9 shows comparison between the two sequences regarding their accuracy measurements in differentiation acute from chronic thrombosis. Statistically significant difference between the two sequences regarding their

sensitivity, specificity, positive predictive value, negative predictive value and accuracy of the test (P value <0.001).

Table 3.9: Comparison between the two sequences regarding their accuracy measurements in differentiation acute from chronic thrombosis.

Variable	CE-MPRAGE	MRV	P value
Sensitivity	86.7%	60.0%	<0.001
Specificity	81.1%	72.7%	<0.001
Positive predictive value	86.7%	75.0%	<0.001
Negative predictive value	81.8%	57.1%	<0.001
Accuracy of the test	88.0%	68.0%	<0.001

Table 3.10 shows comparison of different variables between the patients with normal anatomy and those

with pathological findings on depend to the final reached diagnosis. Statistically significant difference between

them (P value <0.001) for the reason of referral and presence of comorbidities (P value <0.001), while no statistically significant difference between them

regarding the mean of age, gender and duration of headache (P value >0.05) for all of them.

Table 3.10: Factors predicting pathological findings of contrast enhanced /MRV (number = 193).

Variable	Normal findings = 91	Pathological findings = 31	P value
Age, mean ± standard deviation	42.34 ± 13.69	42.83 ± 15.02	0.667
Gender			0.153
-Male	25 (27.48%)	12 (38.71%)	
-Female	66 (72.52%)	19 (41.29%)	
Smoking, number (%)			0.986
-Yes	42 (46.15%)	14 (45.16%)	
-No	44 (48.35%)	15 (48.38%)	
-X-smoker	5 (5.50%)	2 (6.45%)	
Reason for referral			<0.001
-Chronic headache alone	69 (75.82%)	13 (41.93%)	
-Suspected increase intracranial pressure	9 (9.89%)	10 (32.2%)	
-Suspected dural venous stenosis	8 (8.79%)	3 (9.67%)	
- Suspected dural venous thrombosis	5 (5.50%)	5 (16.12%)	
Duration of headache			0.073
-Less than 24 hours	3 (9.12%)	1 (3.23%)	
-1-7 days	18 (19.78%)	10 (32.25%)	
-1 to 4 weeks	59 (64.83%)	13 (41.94%)	
-More than 4 weeks	11 (12.08%)	7 (22.58%)	
Presence of comorbidities			<0.001
-Yes	45 (49.45%)	23 (74.19%)	
-No	46 (50.55%)	8 (25.81%)	

4. DISCUSSION

In the current study, two thirds of the study population were females and the mean age of overall participants was 43 years. Additionally, the main presenting symptom was headache either alone or with other symptoms suggesting the presence of increase intracranial pressure, dural venous thrombosis and to less extent dural venous stenosis. Which are consistent with many studies investigating the clinical and radiological characteristic of patients with headache and suspected intracranial venous disorders. Almegren^[10] found out of the 103 patients presented mainly with headache, 32% were male, and 68% were female, with a mean age of 39 years. Alet et al^[11] also reported among one hundred sixty-two patients, (82% of them had headache), the mean age was 42 years and 72% were women. These findings could be explained by the interplay of females' hormonal and metabolic influencing factors particularly in the period of childbearing, as a result females are more likely to be affected by many venous sinuses disorder such as idiopathic increase of intracranial pressure and venous sinus thrombosis, explaining the higher female referral rate to contrast enhanced and MRV neuroimaging.

Positive smoking history was present in about one third of the patients. Which could suggest a link between smoking and patients presented compliant, such finding usually varied depending on the type of presenting compliant (headache). In a meta-analysis found the

overall prevalence of smoking among patients with headache was 37% (20% in patients with migraine and 65% in cluster headache).^[12]

Additionally, about two thirds of the study patients, had their chief complaint for more than 1 weeks (subacute to chronic rather than acute emergencies) which give a hint for diagnosing the patient disorder. However, certain "red flag" clinical symptoms such as the presence of neurological signs, fever/stiff neck, sudden/severe onset "worst ever" headache or new onset headaches among those aged more than 50 years, or in the presence of head trauma history, or in patients with immunocompromised state, dictate brain MRI indications, rather than headache duration.^[13] In this context no published study found to compare.

The study found about two-thirds of its participants had at least one medical comorbidity, the most common being migraine, hypertension, and diabetes mellitus. These results appeared as a result of migraine high association with intracranial hypertension as shown by a study conducted by Abd-elrazek et al^[14], the same with hypertension, diabetes mellitus and to less extend anemia, multiple sclerosis, brain surgery, current active cancer, previous stroke, postpartum period, recent tuberculosis, blood clotting disorder and systemic lupus erythematosus which agrees Caponnetto et al^[15] study's findings. This indicates that the presence of such

comorbidities might raise the possibility of finding intracranial pathology.

The majority of study patients had normal findings or findings not related to venous sinus pathology, which in agreement with Happonen et al^[4] study findings. Additionally, the study found that is often better than ordinary MRV for showing normal venous architectural findings in spite of 4 patients wrongly diagnosed as normal anatomy but they had anatomical variants. In same way, had closer results to what was finally reached diagnosis than MRV with regard to normal anatomical variants and pathological findings. These results could be occurred due to the fact that is less impacted by slow flow or vessel angle.^[3] Anyhow, the combination of these sequences with other contrast enhanced sequence considerably could improve the diagnostic results as shown by Liang et al^[16] study findings.

On the other hand, the study found significant inter-observer agreement across all of the evaluated categories. Liang et al^[16] showed comparable findings. Additionally, the study found significant inter-method agreement for normal patients, but moderate inter-method agreement for normal anatomical variants and pathological findings, but there is wide difference in the concordance between the evaluated categories. This indicates that, while the sequences frequently agree, they may identify abnormalities differently, as can displays detailed anatomical images of brain tissues (gray matter, white matter, and cerebrospinal space) when conducted after contrast, it emphasizes enhancing lesions and the venous system, making it particularly valuable for analyzing structural changes. While, MRV primary application is to assess blood flow and diagnose venous problems such as blood clots or vascular abnormalities. This difference actually reflects the technical and contrast variations between structural and flow-based imaging. Similar to the study's findings, other studies have compared contrast-enhanced MRI sequences (similar to CE-MPRAGE) to MRV as the reference standard, revealing that different contrast enhanced MRI sequences provide varied levels of agreement with MRV. For example, Saindane et al.^[17] showed moderate agreement ($\kappa = 0.51$) for contrast-enhanced 3D GRE T1-weighted imaging compared to MRV for pathological findings, also the study showed sequence-dependent concordance.

Regarding image quality, the study showed significant difference between CE-MPRAGE and MRV sequence. Suggesting CE-MPRAGE had superior image quality than MRV, which directly affect the diagnostic value for dural venous sinus. In comparison to other studies, Saindane et al.^[17] found that CE-3D GRE (similar to CE-MPRAGE) sequences had clearer vessel borders, less artifact but overall, both sequences provided no significant image quality difference in evaluation of dural venous sinuses. Panyaping et al^[18] found CE-MPRAGE/3D T1 sequences had superior vessel edge

delineation and higher overall clarity scores on a 5-point Likert scale, although overall picture quality values were statistically comparable among the sequences. These disparities could suggest that the superior clarity of CE-MPRAGE and other like sequences does not always mean a significant difference in perceived overall image quality compared with MRV. Anyhow, more studies are needed to solve this conflict of evidence.

In the differentiation of patients with normal venous sinus anatomy from patients with venous sinus pathological findings. The study found that CE-MPRAGE had superior diagnostic performance (in other word, higher sensitivity, specificity, positive predictive value, negative predictive value and overall accuracy of the test). Indicating a greater ability of CE-MPRAGE for detecting both diseased and non diseased cases. Which is agreement with Banihani et al^[3] study findings. Additionally, the study found CE-MPRAGE had superior diagnostic ability than MRV for differentiating patients with normal venous sinus anatomy from patients with normal anatomical variants. Liang et al^[16] showed similar findings. This is due to the fact that CE-MPRAGE is not affected by the angle between scan slab and blood vessels or due to physics (flow velocity) of both techniques.

The other important finding of the current study is the greater ability of CE-MPRAGE in comparison to MRV in differentiating normal anatomical variants from pathological findings, which consistent with Lettau et al^[19] study findings. As MRV frequently causes "flow gaps" or signal loss in locations with slow flow, which can be mistaken as thrombosis. Whereas, CE-MPRAGE clearly shows these hypoplastic sinuses as patent.

Concerning differentiation between acute and chronic thrombus. The study shows CE-MPRAGE had superior diagnostic ability than MRV, which runs with Lettau et al^[19] and Banihani et al^[3] studies' findings However, chronic thrombi can enhance by which can misdiagnosed as a patent vessel or obscure the clot leading to false negative results. Anyhow, in this study no patient with chronic thrombus had such a result. These results imply that CE-MPRAGE is more than just an additional sequence; rather, it might be complementary technique to MRV, particularly in patients with suspected dura venous disease, unclear MRV results, or flow-related abnormalities. By adding CE-MPRAGE to other sequences, the diagnostic accuracy and confidence might be increased without the need for extra contrast.

The study compares between subjects with normal and pathological findings, showing a significant difference regarding the presenting complaint (higher among patients with suspected increase intracranial pressure, acute and chronic thrombosis), which aligns with Momin et al^[20] and Liang et al^[16] studies' findings. In the same way, the study found the presence of comorbidities is significantly predicates CE-MPRAGE and MRV

pathological findings. In contrast, the study found that the mean age, gender, symptom duration was not predicting pathological findings. This indicates that systemic diseases could raise the possibility of having visible intracranial abnormalities and supporting a more cautious imaging approach in individuals with relevant medical histories. Other studies on idiopathic intracranial hypertension have shown that systemic and clinical comorbidities (e.g., elevated body mass index, intracranial pressure changes, and venous sinus stenosis) are more strongly associated with abnormal venous sinus imaging findings than demographic variables such as age or gender.^[21-22] Furthermore, the significance of comorbid conditions in identifying patients at risk of dural venous pathology has been reinforced by similar findings in cerebral venous thrombosis cohorts, where systemic comorbidities such as prothrombotic states, infection, malignancy, and pregnancy have been significantly associated with abnormal imaging findings, while age, sex, and symptom duration were not significant predictors, consistently with the findings of other published studies.^[23-25]

5. CONCLUSION

Contrast enhanced Magnetization prepared Rapid Acquisition Gradient Echo (CE-MPRAGE) had superior sensitivity, specificity, positive predictive value, negative predictive value and accuracy than magnetic resonance venography (MRV) in showing normal venous architectural, normal anatomical variants and diagnosing dural venous disorders. However, the final diagnosis is depended on combination of these sequences. CE-MPRAGE shows important improvement in the diagnostic ability of dural venous abnormalities. CE-MPRAGE should be included as an important part of neuroimaging sequences when dural venous disease is suspected.

ACKNOWLEDGEMENT

We appreciate the assistance offered by the medical staff at Imamain Al Khadhmain Medical City. This study could not have been done without the assistance of each of these people.

Conflict of interest

About this study, the authors disclose no conflicts of interest.

REFERENCES

- Hufnagle JJ, Tadi P. Neuroanatomy, brain veins. InStatPearls [Internet] 2023 Jul. 24. StatPearls Publishing.
- Abdalkader M, Hui F, Amans MR, Raz E, Hanning U, Ma A, Brinjikji W, Malek AM, Oxley TJ, Nguyen TN. Cerebral venous disorders: diagnosis and endovascular management. *Journal of Neuroradiology*, 2023 Nov. 1; 50(6): 581-92.
- Banihani M, Malabeh Q, Shawaqfeh J, Khawaldeh M, AlHazaimeh M. Post-contrast Three-dimensional MP RAGE T1WI Sequence Compared to Brain MRV Sequence for Diagnosing Brain Sinus Venous Thrombosis. *Acta Informatica Medica*, 2024; 32(1): 43.
- Happonen T, Nyman M, Ylikotila P, Kytö V, Laukka D, Mattila K, Hirvonen J. Imaging outcomes of emergency MRI in patients with suspected cerebral venous sinus thrombosis: a retrospective cohort study. *Diagnostics*. 2023 Jun 14; 13(12): 2052.
- da Silva Couceiro AF. Developmental venous anomalies, cerebral cavernous malformations and beyond: neuroimaging insight into pediatric cerebrovenous vascular malformations (Doctoral dissertation, Universidade do Porto (Portugal)).
- Sarma A, Martin D, Pruthi S, Jones R, Little SB. Imaging the cerebral veins in pediatric patients: beyond dural venous sinus thrombosis. *Radiographics*. 2023 Jan 19; 43(2): e220129.
- Jianu DC, Jianu SN, Iacob N, Dan TF, Munteanu G, Gogu AE, Petrica L. Cerebral Veins and Dural Sinuses Thrombosis: State-of-the-Art Diagnosis. *InStroke-Management Pearls 2023 Jun 28*. Intech Open.
- AL-Ani MI, Fahed QA, Shyaa AI. Clinical Importance of Imaging Anatomical Signs in Predicting Transverse Sinus Dominance Using Conventional Magnetic Resonance Imaging. *Journal of the Faculty of Medicine Baghdad*. 2023 Apr 27; 65(1): 14-9.
- Epomedicine. Dural Reflections and Venous Sinuses [Internet]. Epomedicine; 2016 Aug 1 [cited 2025 Dec 23].
- Almegren M. Clinical and radiological characteristics of cerebral vein thrombosis: a retrospective study. *Bleeding, Thrombosis, and Vascular Biology 2023*; 2: 85.
- Alet M, Ciardi C, Alemán A, Bando L, Bonardo P, Cea C, Cirio J, Cossio J, Cuculic M, Esnaola MM, García-Pérez F. Cerebral venous thrombosis in Argentina: clinical presentation, predisposing factors, outcomes and literature review. *Journal of Stroke and Cerebrovascular Diseases*. 2020 Oct 1; 29(10): 105145.
- Błaszczak B, Martynowicz H, Przegrzałek J, Niemiec P, Straburzyński M, Budrewicz S, Waliszewska-Prosół M. Smoking in primary headaches - a systematic review and meta-analysis. *J Headache Pain*. 2025 Jun 4; 26(1): 133.
- Do TP, Remmers A, Schytz HW, Schankin C, Nelson SE, Obermann M, Hansen JM, Sinclair AJ, Gantenbein AR, Schoonman GG. Red and orange flags for secondary headaches in clinical practice: SNNOOP10 list. *Neurology*. 2019 Jan 15; 92(3): 134-144.
- Abd-elrazek GM, Elmalky I, Saddiq AM, Abd-el Wahab SM. Diagnostic value of MRI and MRV in Migraine indicating intracranial hypertension. *SVU-International Journal of Medical Sciences*. 2024 Jan 1; 7(1): 345-54.
- Caponnetto V, Deodato M, Robotti M, Koutsokera M, Pozzilli V, Galati C, Nocera G, De Matteis E, De

- Vanna G, Fellini E, Halili G, Martinelli D, Nalli G, Serratore S, Tramacere I, Martelletti P, Raggi A; European Headache Federation School of Advanced Studies (EHF-SAS). Comorbidities of primary headache disorders: a literature review with meta-analysis. *J Headache Pain*. 2021 Jul 14; 22(1): 71.
16. Liang L, Korogi Y, Sugahara T, Onomichi M, Shigematsu Y, Yang D, Kitajima M, Hiai Y, Takahashi M. Evaluation of the intracranial dural sinuses with a 3D contrast-enhanced sequence: prospective comparison with 2D-TOF MR venography and digital subtraction angiography. *American Journal of Neuroradiology*. 2001 Mar. 1; 22(3): 481-92.
 17. Saindane AM, Mitchell BC, Kang J, Desai NK, Dehkharghani S. Performance of spin-echo and gradient-echo T1-weighted sequences for evaluation of dural venous sinus thrombosis and stenosis. *AJR Am J Roentgenol*. 2013 Jul; 201(1): 162-9.
 18. Panyaping T, Wongpanich G, Sangfai O, Tritanon O. Comparison of contrast-enhanced 3D spoiled gradient-echo high-resolution T1-weighted sequences versus contrast-enhanced MR venography for detection of dural venous sinus thrombosis. *Ramathibodi Medical Journal*. 2018 Jun 21; 41(2): 44-53.
 19. Lettau M, Laible M, Barrows RJ, Heiland S, Bendszus M, Hähnel S. 3-T contrast-enhanced MR angiography with parallel imaging in cerebral venous and sinus thrombosis. *J Neuroradiol*. 2011 Dec; 38(5): 275-82.
 20. Momin AA, Musmar B, El Naamani K, Mouchtouris N, Self DM, Lan M, Piper K, Ritz C, Tjounmakaris SI, Jabbour PM, Gooch MR. Predictors of dural venous sinus pressure gradient in patients with idiopathic intracranial hypertension. *J Neurosurg*. 2025 Mar 7; 143(2): 543-549.
 21. Ridha MA, Saindane AM, Bruce BB, Riggeal BD, Kelly LP, Newman NJ, Biousse V. MRI findings of elevated intracranial pressure in cerebral venous thrombosis versus idiopathic intracranial hypertension with transverse sinus stenosis. *Neuro-ophthalmology (Aeolus Press)*. 2013 Feb 1; 37(1): 1-6.
 22. Durst CR, Ornan DA, Reardon MA, Mehndiratta P, Mukherjee S, Starke RM, Wintermark M, Evans A, Jensen ME, Crowley RW, Gaughen J. Prevalence of dural venous sinus stenosis and hypoplasia in a generalized population. *Journal of neurointerventional surgery*. 2016 Nov 1; 8(11): 1173-7.
 23. Saposnik G, Barinagarrementeria F, Brown Jr RD, Bushnell CD, Cucchiara B, Cushman M, Deveber G, Ferro JM, Tsai FY. Diagnosis and management of cerebral venous thrombosis: a statement for healthcare professionals from the American Heart Association/American Stroke Association. *Stroke*. 2011 Apr; 42(4): 1158-92.
 24. Ferro JM, Canhão P, Stam J, Boussier MG, Barinagarrementeria F. Prognosis of cerebral vein and dural sinus thrombosis: results of the International Study on Cerebral Vein and Dural Sinus Thrombosis (ISCVT). *Stroke*. 2004 Mar 1; 35(3): 664-70.
 25. Coutinho JM. Cerebral venous thrombosis. *Journal of Thrombosis and Haemostasis*. 2015 Jun; 13: S238-44.