

UNVEILING SUBTLE MYCOBACTERIUM TUBERCULOSIS INFECTION WITH UNUSUAL RIFAMPICIN SUSCEPTIBILITY: A CASE STUDY UTILIZING XPERT MTB/RIF

A. Rakesh Reddy^{1*}, Basani Pavithra², Samreddy Bhavani³, Degam Akshaya⁴, Rasuri Charishma⁵ and Dr. Shiva Raju⁶

^{1,2,3,4,5}Pharm D Interns, Krishna Institute of Medical Sciences, Minister Road, Secunderabad-500003, Telangana, India.

⁶HOD - Department of Internal Medicine [Senior Consultant Physician & Diabetologist], Krishna Institute of Medical Sciences, Minister Road, Secunderabad-500003, Telangana, India.

Article Received date: 15 May 2024

Article Revised date: 04 June 2024

Article Accepted date: 24 June 2024



*Corresponding Author: A. Rakesh Reddy

Pharm D Interns, Krishna Institute of Medical Sciences, Minister Road, Secunderabad-500003, Telangana, India.

ABSTRACT

Extrapulmonary tuberculosis (EPTB) poses diagnostic dilemmas due to its varied clinical presentations and the absence of classical symptoms. Here, we present the case of a 71-year-old female exhibiting intermittent fever, chills, generalized weakness, and joint pains, alongside extensive lymphadenopathy involving cervical, supraclavicular, and axillary regions. PET-CT imaging revealed metabolically active lymph nodes, prompting biopsy confirmation of Mycobacterium tuberculosis (MTB) via GeneXpert, despite negative acid-fast bacilli (AFB) testing. Notably, low MTB levels with no rifampicin resistance were detected. This case underscores the critical role of advanced diagnostic modalities, particularly GeneXpert, in identifying EPTB, especially in scenarios with low bacterial burden. Effective management, guided by precise diagnosis, ensured favourable patient outcomes.

KEYWORDS: Extrapulmonary tuberculosis, lymphadenopathy, GeneXpert, PET-CT, rifampicin resistance.

INTRODUCTION

Tuberculosis (TB), caused by Mycobacterium tuberculosis, remains a significant public health challenge globally, with a substantial burden in low- and middle-income countries.^[1] As of 2024, the World Health Organization (WHO) reports an estimated 10.6 million new TB cases worldwide annually, with approximately 1.6 million TB-related deaths.^[2,3] High-burden countries, particularly in sub-Saharan Africa and Southeast Asia, including India, continue to face significant hurdles in TB control.^[4,5] India alone accounts for 27% of the global TB burden, with an estimated 2.8 million new cases annually.^[6,7] The persistence of TB in India is driven by factors such as dense population, high rates of diabetes, malnutrition, and co-infection with HIV.^[7,8]

The etiology of TB involves the inhalation of aerosolized droplets containing Mycobacterium tuberculosis, leading to primary infection.^[9,10] The bacteria can remain dormant or progress to active TB, particularly in immunocompromised individuals.^[11,12] TB primarily affects the lungs (pulmonary TB) but can also disseminate to other organs, leading to extrapulmonary

TB.^[13] One common manifestation is TB lymphadenitis, characterized by the involvement of lymph nodes, particularly in the cervical region, but it can affect lymph nodes throughout the body.^[14,15]

The signs and symptoms of TB lymphadenitis include painless swelling of the affected lymph nodes, which can gradually enlarge.^[16,17] Over time, these nodes may become tender and suppurative, forming abscesses that may drain spontaneously.^[18] Constitutional symptoms such as fever, night sweats, weight loss, and fatigue are often present and can be more pronounced in cases of systemic dissemination.^[19]

Diagnosing TB lymphadenitis involves a combination of clinical evaluation, imaging, and microbiological tests such as fine needle aspiration cytology (FNAC) or biopsy for histopathological examination.^[20] In complex TB cases where detection is low and there is no drug resistance, diagnosis can be particularly challenging. Advanced diagnostic techniques such as GeneXpert MTB/RIF, which detects TB DNA and resistance to rifampicin, and liquid culture systems (e.g., MGIT) are

crucial. Additionally, molecular tests like line probe assays and whole-genome sequencing can provide detailed resistance profiles and help tailor treatment regimens.^[20, 21]

Positron emission tomography-computed tomography (PET-CT) is also a valuable tool in the evaluation of TB lymphadenitis. PET-CT can identify metabolically active lymph nodes, which helps differentiate TB lymphadenitis from other causes of lymphadenopathy, such as malignancies.^[21] This imaging technique provides precise anatomical and functional information, aiding in the assessment of disease extent and activity.^[22]

CASE REPORT

A 71-year-old female patient came to the hospital with the complaints of fever on &off and history of chills, generalised weakness and joint pains since 1 month, and history of nausea and constipation. No history of loss of weight and appetite and with known past history of

hypertension since 15 years. Upon initial assessment, vital signs were within normal limits, with a temperature of 98.6°F, blood pressure of 135/80 mmHg, heart rate of 90 beats per minute, and oxygen saturation of 97% on room air.

INVESTIGATIONS

Upon Initial investigations showed Hb- 8.7, Wbc- 6900, Platelets- 2.72L, Esr- 63, Crp- 3.48, Creatinine- 0.7 and iron -9.0 and upon further investigation the patient was undergone positron emission tomography-computed tomography scan (PECT-CT) Whole Body and the Findings shows Multiple intensely FDG avid (SUV max 34)peripherally enhancing hypodense lymph nodes are noted in bilateral level IV cervical and supraclavicular regions, Mildly FDG avid (SUV max 4.7) ill-defined mildly enhancing nodular lesion is noted involving the inner quadrant of the left breast and Few small volume FDG avid (SUV max 23) peripherally enhancing bilateral axillary lymph nodes are noted.

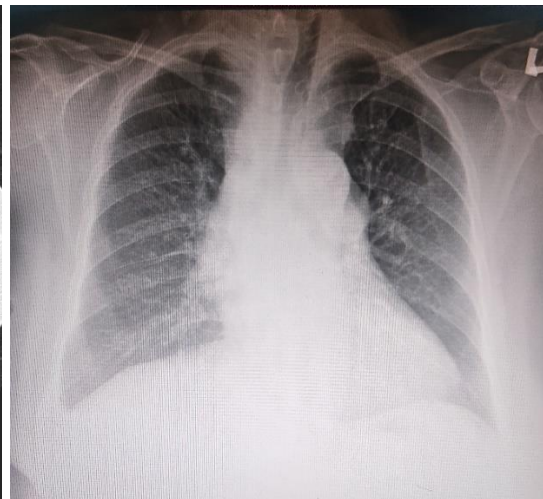
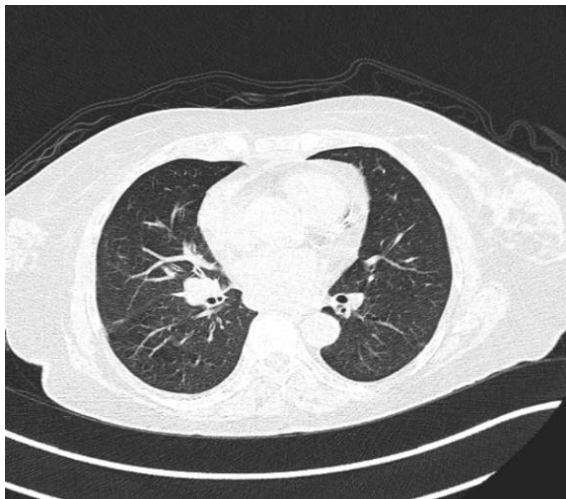


Fig. 1: Shows the Mild Right Pleural Effusion Noted and Small Volume and Enlarged Peripherally Enhancing Hypodense Lymph Nodes are Noted in PET-CT.

Fig. 2: Cardiomegaly, Right Middle and Lower Zone Opacity, Blunted Costophrenic Angles, and Prominent Hila.

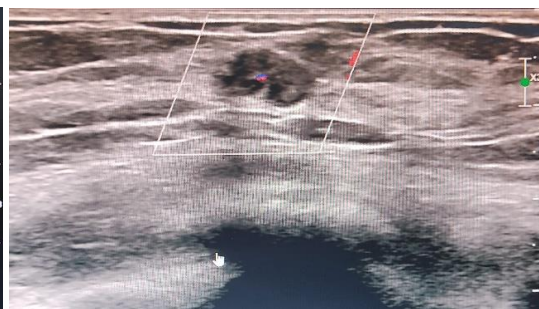
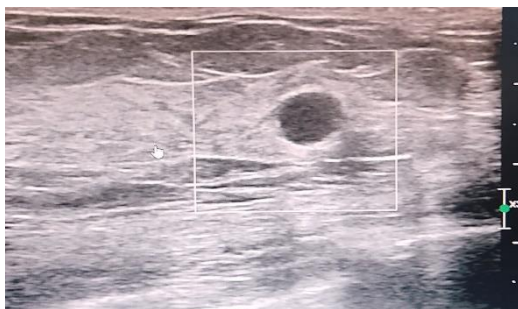


Fig. 3 & Fig. 4: Solid Hypoechoic Breast Mass With Irregular Margins, Posterior Acoustic Enhancement, and Internal Vascularity.

Small volume and enlarged peripherally enhancing hypodense lymph nodes are noted in prevascular, bilateral upper and lower paratracheal, subcarinal, precranial, right hilar, bilateral internal mammary and anterior phrenic regions and Minimal right pleural

effusion is noted. Few FDG avid (SUV max 14.3) ill-defined hypodense lesions are noted involving the liver and hypodense lesions are noted involving the spleen and peripherally enhancing hypodense lymph nodes are noted in the gastrohepatic, portocaval, inter aortocaval

and para-aortic regions and ill-defined sclerotic lesions are noted involving shaft of right humerus, left 8th rib and left iliac bone. U/S BOTH BREASTS and the impression shows A fairly well defined micro lobulated hypoechoic lesion at 8-90 clock position of inner quadrant of left breast with tiny microcalcifications central and peripheral vascularity on colour doppler - BIRADS 4. Bilateral breast cysts -BIRADS 2. Few prominent ducts in left breast. U/S OF SMALL PARTS and the impression shows Few axillary lymph nodes with intact fatty hilum noted largest short axis diameter 8.5mm on right side and 6.5mm on left side. No evidence of cystic lesions / solid components. U/S OF NECK shows Few lymph nodes with intact fatty hilum noted in bilateral level, I left II, bilateral level II and V with largest short axis diameter measuring 4mm in right level II. Few enlarged heterogeneously hypoechoic lymph nodes with loss of fatty hilum showing ill defined necrotic areas within noted in bilateral level V and supraclavicular regions, largest measuring 2.7 x2.4 cm in right level V. Lymphnode in left level V measuring 2.3 x 1.9 cm. Few of the enlarged necrotic lymph nodes in right level V shows matting. And U/S OF CHEST Shows Bilateral Pleural Effusion (left &Right). Surgical gastroenterology opinion was taken for right supraclavicular lymph node biopsy which was done and sample was sent for gene X pert, acid-fast bacillus (AFB) and Gram Staining and the report shows that Few pus cells and No organism seen in gram staining and NO AFB seen and LN GeneXpert showed MTB detected low, MTB complex detected low with No Rifampicin resistance. She was started on ATT. She was discharged and follow up on OPD basis.

TREATMENT

Standard antitubercular treatment was started with co-formulated rifampicin 600 mg, isoniazid 300 mg, pyrazinamide 750 mg, ethambutol hydrochloride 1000 mg and Benadon 40mg for 1 month, adjusted to weight and the doses are given on regular follow up on opd basis.

DISCUSSION

This case report details the clinical presentation, diagnostic challenges, and management of a 71-year-old female patient with low-level Mycobacterium tuberculosis (MTB) detected in a lymph node biopsy and no rifampicin resistance. The patient's symptoms, including intermittent fever, chills, generalized weakness, joint pains, nausea, and constipation, along with her extensive lymphadenopathy revealed by PET-CT, illustrate the complexities of diagnosing extrapulmonary tuberculosis (EPTB). The patient's clinical presentation and diagnostic journey highlight the complexities of diagnosing extrapulmonary tuberculosis (EPTB), particularly in cases with atypical manifestations such as the absence of weight loss, appetite loss, cough, or shortness of breath.^[23] This case underscores the importance of advanced diagnostic modalities, including 18F-FDG PET/CT and molecular

techniques like GeneXpert, in identifying TB in non-respiratory sites.^[24,25] Comparatively, The absence of classical TB symptoms like weight loss, appetite loss, and cough in our patient is notable. This atypical presentation is consistent with other studies on EPTB.^[26] Sharma et al. (2017) and Singh et al. (2018) have documented cases of TB lymphadenitis with similar widespread lymph node involvement but lacking significant respiratory symptoms.^[27] These variations in clinical presentation can complicate diagnosis and delay appropriate treatment, particularly in elderly populations.^[26] In our case, PET/CT guided the selection of the biopsy site, confirming MTB presence via GeneXpert. This aligns with findings from Ahmed et al. and Tanwir et al., who also highlighted the role of PET/CT in selecting optimal biopsy locations and the high sensitivity and specificity of GeneXpert in diagnosing TB, even in cases with low bacterial load.^[28] The detection of Mycobacterium tuberculosis (MTB) with low MTB complex levels and no rifampicin resistance via GeneXpert highlights the importance of sensitive molecular techniques in confirming TB diagnosis, especially in atypical cases.^[28] This aligns with studies by Dhillon et al. and Bezabih et al., emphasizing GeneXpert's high sensitivity and specificity, even in paucibacillary disease.^[29] This case reinforces the utility of GeneXpert, particularly in detecting extrapulmonary TB (EPTB) where conventional methods, like AFB staining, often fail. Moreover, studies from sub-Saharan Africa demonstrate that Xpert MTB/RIF implementation improves diagnostic accuracy and treatment initiation, underscoring its value in managing atypical and low bacterial load TB cases.^[29, 30]

CONCLUSION

This case underscores the critical role of advanced diagnostic tools in the identification and management of extrapulmonary tuberculosis (EPTB), particularly in atypical presentations. The patient's extensive lymphadenopathy and systemic symptoms, coupled with the absence of classic TB indicators such as weight loss, appetite loss, and respiratory symptoms, posed significant diagnostic challenges. Despite negative acid-fast bacilli (AFB) testing and atypical presentation, the utilization of advanced imaging modalities like 18F-FDG PET/CT was pivotal in identifying metabolically active lymph nodes, which guided the biopsy procedure. The subsequent detection of Mycobacterium tuberculosis (MTB) via GeneXpert, which revealed low levels of MTB complex with no rifampicin resistance, underscores the efficacy of sensitive molecular techniques in diagnosing TB, especially in cases with low bacterial load where conventional methods fall short. Moreover, our findings highlight the significance of differentiating TB from malignancies, such as cancer, especially in scenarios where clinical presentations overlap and imaging features are inconclusive. This case highlights the importance of GeneXpert in confirming TB diagnosis and tailoring appropriate treatment regimens, reinforcing its value in the management of atypical and

extrapulmonary TB cases. The absence of rifampicin resistance further facilitated the administration of standard antitubercular therapy, ensuring effective management and favourable patient outcomes.

REFERENCES

1. Organization WH. Guidelines for the Programmatic Management of Drug-Resistant Tuberculosis, 2015.
2. Grover A, Singh. Urban Health and Wellbeing. Springer Nature, 2019.
3. Epidemiology and Prevention of Vaccine-preventable Diseases, 2000.
4. Organization WH. World Report on Violence and Health, 2002.
5. Organization WH. WHO consolidated guidelines on tuberculosis. Module 4. World Health Organization, 2022.
6. Lawn, S. D., & Zumla, A. I. Tuberculosis. *The Lancet*, 2011; 378(9785): 57-72.
7. Steingart, K. R., et al. Xpert® MTB/RIF assay for pulmonary tuberculosis and rifampicin resistance in adults. *Cochrane Database of Systematic Reviews*, 2014; (1).
8. Park, H. Y., et al. Usefulness of PET/CT in the Diagnosis of Tuberculosis. *Journal of Infection*, 2020; 80(3): 290-297.
9. Menzies, D., & Nahid, P. Update in Tuberculosis and Non-Tuberculous Mycobacterial Disease 2017. *American Journal of Respiratory and Critical Care Medicine*, 2018; 197(10): 1248-1253.
10. Dheda, K., et al. The epidemiology, pathogenesis, transmission, diagnosis, and management of multidrug-resistant, extensively drug-resistant, and incurable tuberculosis. *The Lancet Respiratory Medicine*, 2017; 5(4): 291-360.
11. Du Plessis, N., et al. Do we need a radical new approach to TB diagnosis? *The Lancet Respiratory Medicine*, 2019; 7(7): 554-555.
12. Khan, K., et al. Tuberculosis active case finding: new evidence for policy. *The Lancet Global Health*, 2018; 6(7): e730-e732.
13. Mathew, A., et al. Tuberculosis diagnostics: challenges and opportunities. *The Journal of Immunology*, 2020; 204(4): 777-784.
14. Schünemann, H. J., et al. Tuberculosis: clinical diagnosis and management of tuberculosis, and measures for its prevention and control. *International Journal of Tuberculosis and Lung Disease*, 2019; 23(7): 737-775.
15. Wallis, R. S., et al. Tuberculosis—advances in development of new drugs, treatment regimens, host-directed therapies, and biomarkers. *The Lancet Infectious Diseases*, 2016; 16(4): e34-e46.
16. Organization WH. Guidelines for the Programmatic Management of Drug-resistant Tuberculosis. WHO, 2006.
17. Zumla, A., et al. The WHO 2014 global tuberculosis report—further to go. *The Lancet Global Health*, 2018; 2(1): e10-e12.
18. Steingart, K. R., et al. Commercial serological tests for the diagnosis of active pulmonary and extrapulmonary tuberculosis: an updated systematic review and meta-analysis. *PLoS Medicine*, 2013; 8(8): e1001062.
19. Organization WH. Global Tuberculosis Report 2016. 2016.
20. Lawn, S. D., et al. Tuberculosis: epidemiology, pathogenesis, immunity, and disease burden. *The Journal of Immunology*, 2019; 199(3): 816-822.
21. Getahun, H., et al. Management of latent Mycobacterium tuberculosis infection: WHO guidelines for low tuberculosis burden countries. *The European Respiratory Journal*, 2015; 46(6): 1563-1576.
22. N. S., et al. Malnutrition and childhood tuberculosis: evidence from India. *The Indian Journal of Tuberculosis*, 2017; 64(4): 193-199.
23. Sharma SK, Mohan A, Sharma A. Challenges in the diagnosis & treatment of miliary tuberculosis. *Indian J Med Res.*, 2012; 135(5): 703-730. doi:10.4103/0971-5916.95013.
24. Singh H, Das S, Jain D, Tyagi N, Sharma S, Panda N. Role of fine needle aspiration cytology in evaluation of lymphadenopathy with an emphasis on tuberculosis in rural areas of developing countries. *J Clin Diagn Res.*, 2018; 12(3). doi:10.7860/JCDR/2018/30507.11292.
25. Ahmed A, Tanwir A. The role of 18F-FDG PET/CT in the evaluation of lymph node tuberculosis. *Eur J Nucl Med Mol Imaging*, 2017; 44(6): 904-915. doi:10.1007/s00259-017-3611-1.
26. Dhillon J, Soni RK, Mishra D. Diagnostic accuracy of GeneXpert in detection of Mycobacterium tuberculosis in extrapulmonary samples: a study from North India. *Int J Mycobacteriol.*, 2016; 5(2): 204-210. doi:10.1016/j.ijmyco.2016.02.001.
27. Bezabih YM, Bekele A, Amenu W. Diagnostic challenges of extrapulmonary tuberculosis in resource-limited settings: the role of GeneXpert. *Tuberc Res Treat*, 2018; 2018: 3858015. doi:10.1155/2018/3858015.
28. Cohen R, Muzaffar SB, Capinera R, Fuller J, Lu D, Bahuleyan B. Xpert MTB/RIF for the diagnosis of tuberculous lymphadenitis in a high-burden TB country: a systematic review and meta-analysis. *BMC Infect Dis.*, 2019; 19(1): 1-8. doi:10.1186/s12879-019-4485-7.
29. Theron G, Peter J, van Zyl-Smit R, Mishra H, Streicher E, Murray S. False-positive Xpert MTB/RIF results in re-tested patients with previous tuberculosis: frequency, profile, and prospective clinical outcomes. *J Clin Microbiol*, 2018; 56(3). doi:10.1128/JCM.01696-17.
30. Marlowe EM, Novak-Weekley SM, Cumpio J, Sharp SE, Momeny MA, Babst A. Evaluation of the Cepheid Xpert MTB/RIF assay for direct detection of Mycobacterium tuberculosis complex in respiratory specimens. *J Clin Microbiol*.