

COMPLICATION OF MRSA BACTERIEMIA AND M/XDR GRAM -NEGATIVE INFECTION

G. Kiliptari*¹, Grigol Nemsadze²

¹Head of Critical Care of Central University Clinic After Kipshidze. Professor of TSMU.

²Head of Radiology Department of Central University Clinic after Kipshidze.

Received date: 01 March 2023

Revised date: 21 March 2023

Accepted date: 11 April 2023

*Corresponding Author: G. Kiliptari

Head of Critical Care of Central University Clinic After Kipshidze. Professor of TSMU.

ABSTRACT

Bacteremia caused by *Staphylococcus aureus* is a serious infection associated with high morbidity and mortality and often results in infective endocarditis, abscess of lung, which have a negative impact on patient outcomes. Highly virulent, antibiotic-resistant strains such as methicillin-resistant *S. aureus* (MRSA) are particularly challenging to treat. In *S. aureus*-induced pneumonia, the intense inflammatory response leads to severe lung injury and ARDS. We present a case to highlight the need for prolonged treatment and close monitoring of patients especially with complications associated with *S. aureus* bacteremia. The patient was transferred from the clinic, where he was admitted for paraplegia of the lower extremities, transverse myelitis was diagnosed. He underwent pulse therapy with methylpredizolone, due to the deterioration of his condition, he was transferred to the intensive care unit of our hospital. The patient underwent repeated examinations and was diagnosed with an epidural abscess at the level of the C5-Th1 vertebrae.

KEYWORDS: Epidural Abscess, ARDS, Endocarditis.

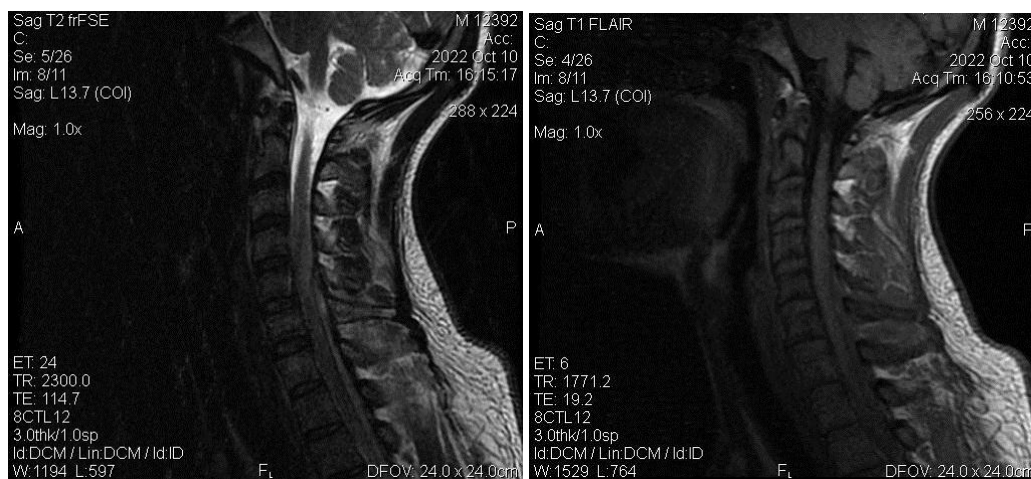
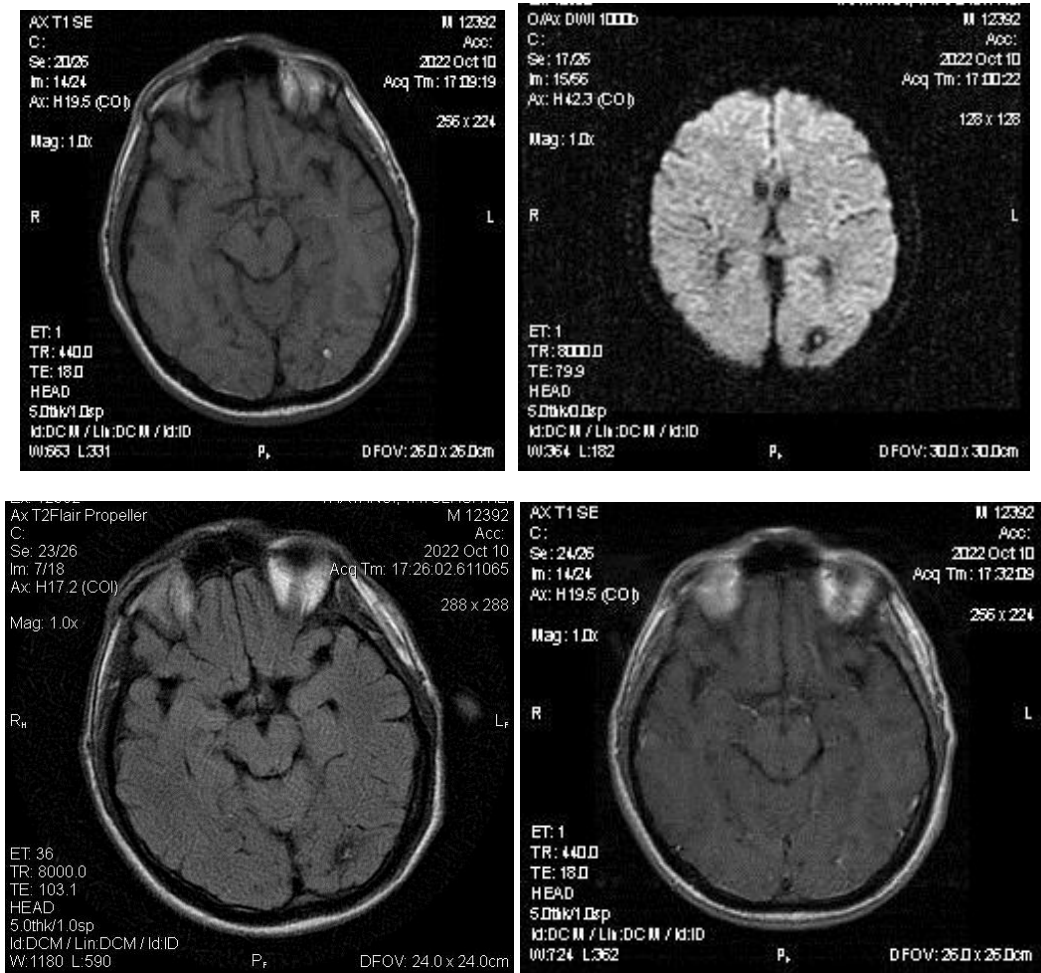


Fig 1: MRI of the cervical vertebrae. Sagittal section.

In the posterior epidural space at the level of C5-Th1 vertebrae, there is an area of viscous-fluid intensity (an epidural abscess is possible), which causes compression of the posterior cerebrospinal fluid space and the spinal cord in these segments, intervertebral discs are characterized with normal intensity signal (October 10, 2022).



Pict 2: (10.10.22) MRI of the brain. Diffusion limited imaging.

T1 in. T2 weighted image. dT1-weighted image with contrast enhancement. In the left occiput, subcortical Irregular, oval-shaped small high-intensity anomalous focus (SE T1, FLAIR T2) and hypointense (FRFSE T2) with a calcified area. After the introduction of a contrast agent (Magnevist 0.5 mmol/ml, 20 ml IV), the MRI picture of the brain does not change, the inclusion of contrast is not fixed. An MRI revealed an acute microhemorrhagic focus in the left and occipital part of the brain.

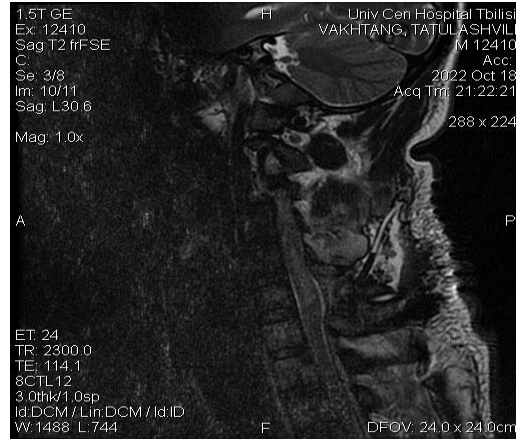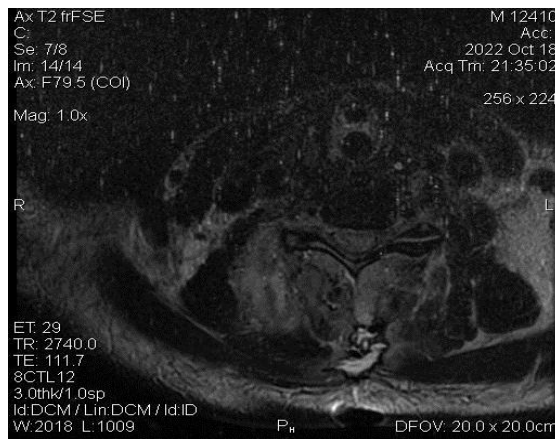
Conducted surgical treatment - drainage of the epidural abscess. Bacteriological investigation of the sputum, blood and wound, was revealed Staphylococcus aureus (MRSA). The presence of *S. aureus* in the bloodstream (bacteremia) was lead to the development of sepsis, *S. aureus* sepsis and later endocarditis. Patient is on mechanical ventilation, in coma state, with unstable hemodynamic and under pressors support, fever. CSF results revealed

meningitis, and treatment of staphylococcal infection in the blood continues, as well as antibacterial treatment of meningitis.

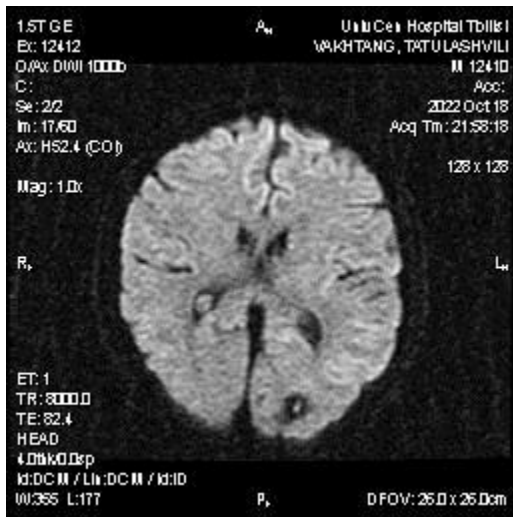
CSF analysis (table 1) revealed high level of protein and cytosis

Table 1

CSF 10.10.22	
CMV IgM	neg
CMV IgG	7.6 iu/ml (pos> 0.5 arbU/ ml)
EBV—VCA IgM	neg
EBV-VCA IgG	96 arbU/ml (pos >5arbU/ml)
CSF (10.10 22)	
Protein	5930 mg/l
Leicocyte	0.512 X 10 ³ /mkl
Eritrocyte	0.001X10 ⁶ /mkl
TC-BF	0.512 X 10 ³ /mkl



On the obtained MRI scans: compared to the previous study (October 10, 2020), viscous fluid is no longer fixed in the posterior epidural space at the level of C5-Th1 vertebrae. A postoperative bone (arcoflavotomy) defect was found in both C6-C7 arches. In the operated area - a drainage tube. Both right paravertebral soft tissues were damaged at the level of C4-C7 vertebrae (10/18/2022).



Pict 4: MRI of the brain.

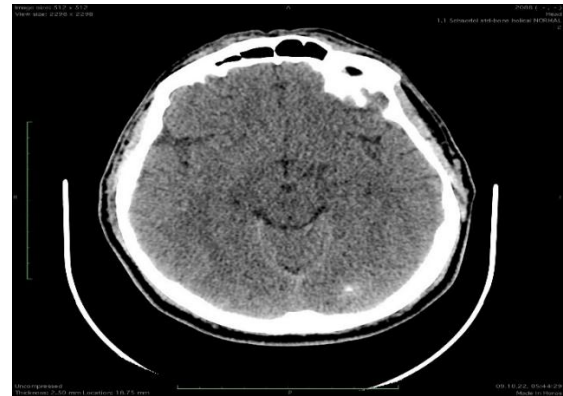On MRI, the picture is not changed, no acute intracerebral process has been detected. (10/18/2022)

CSF analysis revealed changes (table2)

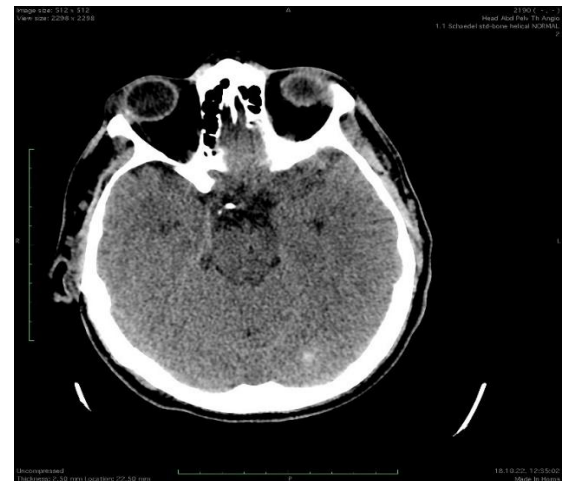Table 2.

CSF (18.10 .22)	
Protein	10773 mg/l
WbC_BF	0.045 X10 ³ /mkl (n <0.005)
TC-BF	0.045X10 ³ /mkl
glucose	3.89mmol/l
MN%	23%
PMN%	85%

On the axial section in the left occipital lobe, the contours are indistinct, a small hyperdense focus. midstructures are not displaced(09/10/2022)

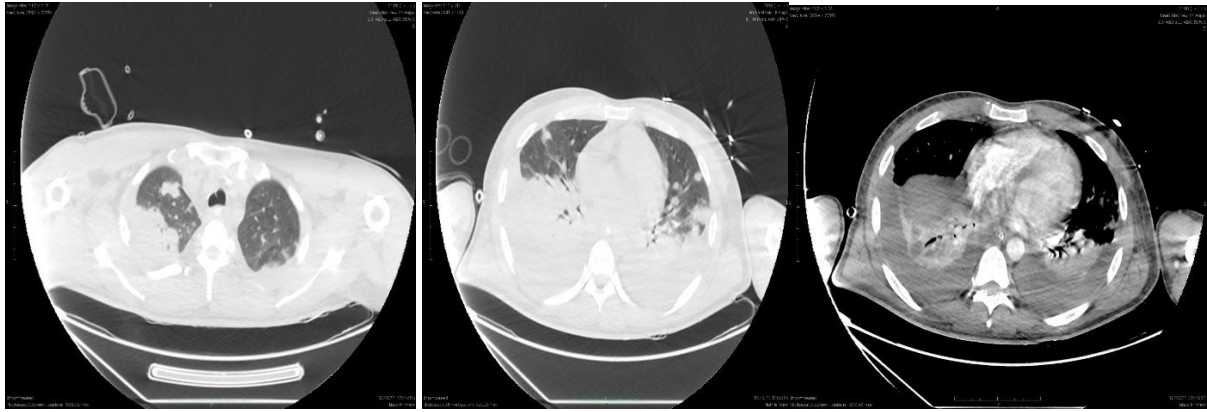


Pict 5: CT scan of the brain.



Pict 6: CT scans of the brain.

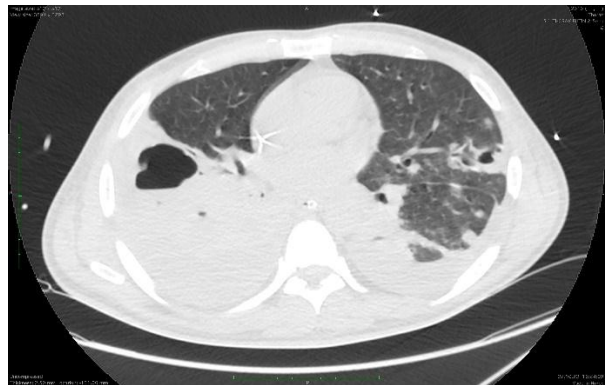
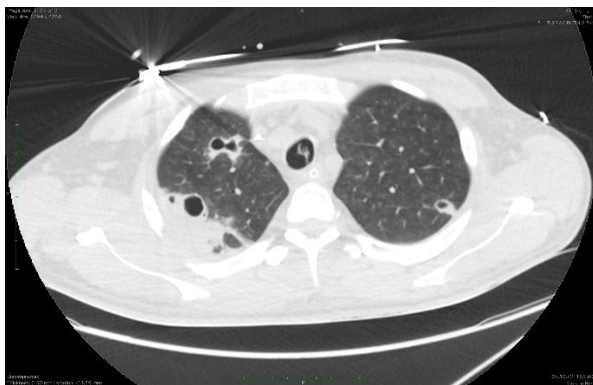Sputum (17.10) bacteriological analysis revealed Staphylococcus aureus (MRSA). The patient's condition worsened due to the development of severe respiratory distress syndrome. In the lung parenchyma, extensive infiltration changes of the consolidation type with subtotal distribution are detected on both sides, against which there are also different localization foci of density, in the right lower lobe, against the background of consolidation, there are also areas of liquid density. There is free fluid in both pleural cavities, stratification on the right 3.4 cm, on the left 3.7 cm. Free air was not detected.(10/18/2022 . pict 7)



Pict.7 CT scan of the chest, with contrast enhancement.

Focal infiltrative changes with a central destruction are observed in the upper lobes of bilateral lungs. In the lower lobes there are extensive consolidated infiltrative changes, on the right in the background there are several

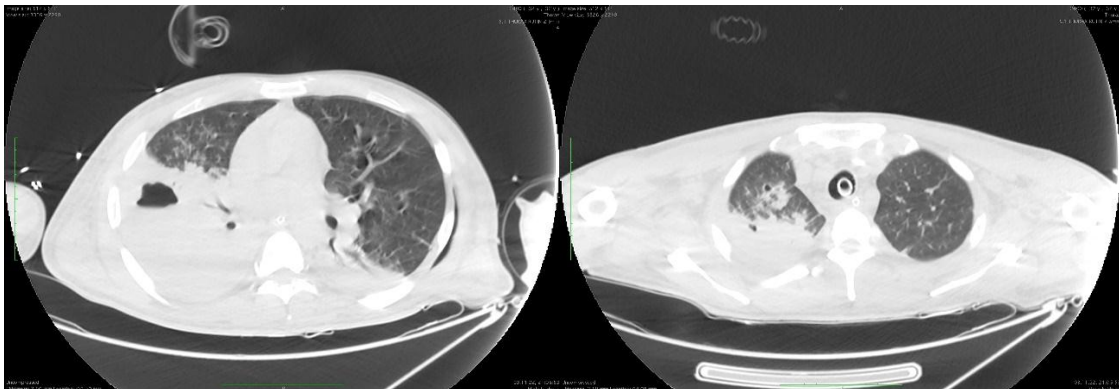
areas of low density and a 4.5 cm cavity containing gas and liquid (horizontal liquid level). In the pleural cavity on both sides of the free fluid, bundle 5.2 cm on the right. 3.2 cm to the left (10/27/2022-pict 8).

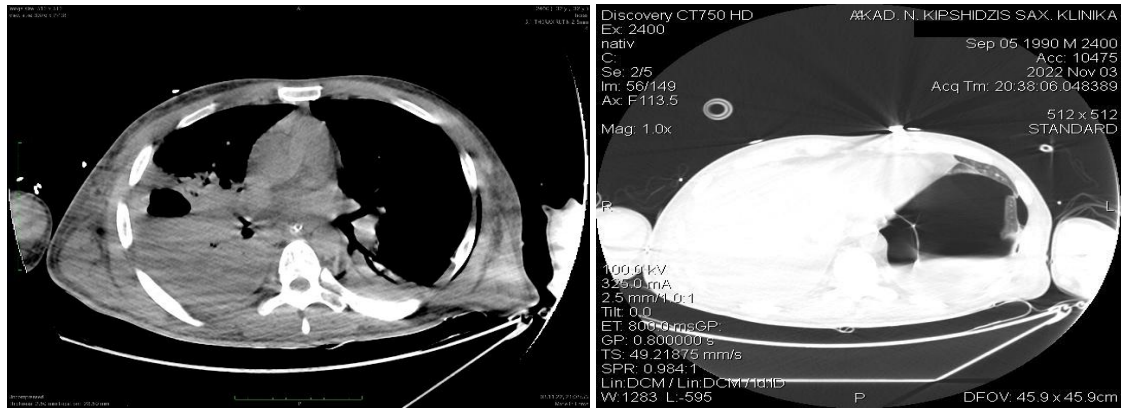

Pict 8: CT scan of the chest cavity.

In the left pleural cavity was detected free air. Focal infiltrative changes with central tissue damage are observed in the upper lobes of the lungs. In the lower lobes, consolidated infiltrative changes are expressed with several areas of reduced density, on the right

cavitation containing air and liquid, revealed a horizontal level of a liquid. There is free fluid in the pleural cavity on both sides, separation 3.7 cm on the right. 2.5cm –left (pict. 9)





Pict 9 CT chest.

The pleural cavity of patient was drained. Patient is on mechanical ventilation PaO₂/ FiO₂ < 100 mm.Hg. CSF changes is presented in table. 3.

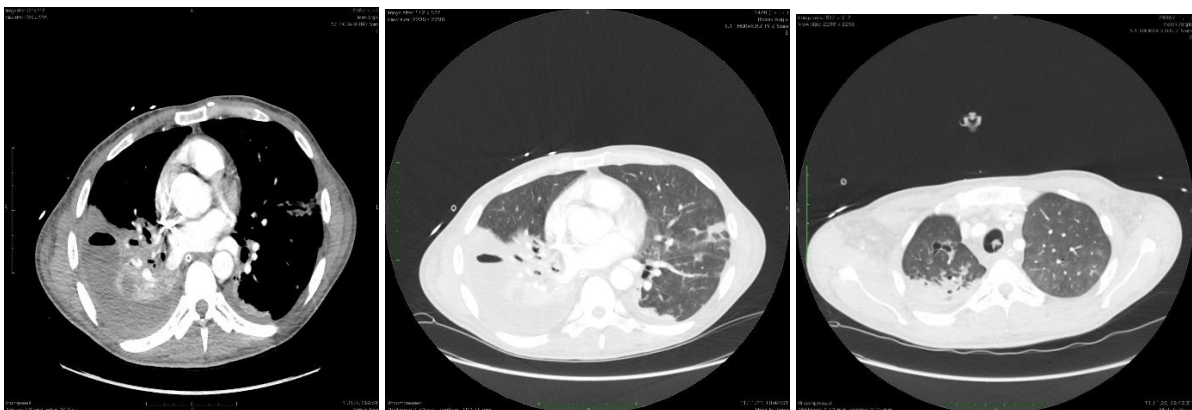
Table 3.

CSF (22/10.22)	
Protein	3098 mg/l (n 200-400 mg/l)
Glucose	2.17 mmol/l (2.22-3.89)
WBC -BF	0.041
RBc --BF	0.001 X10 ³ /mkl
TC--BF	0.041 X10 ⁴ /mkl
PMN %	24.4%
MN %	75.65

Angiographic examination does not reveal filling defects in the pulmonary trunk and bilateral main, lobar and segmental arteries, there are no reliable signs of thrombosis. Focal infiltrative changes with a central destruction are observed in the upper lobes of the lungs. Consolidated infiltrative changes are determined in the

lower lobes, there is free fluid in the pleural cavity on both sides, stratification on the right 2.5 cm. 0.5 cm to the left (11/11/2022—pict 10).

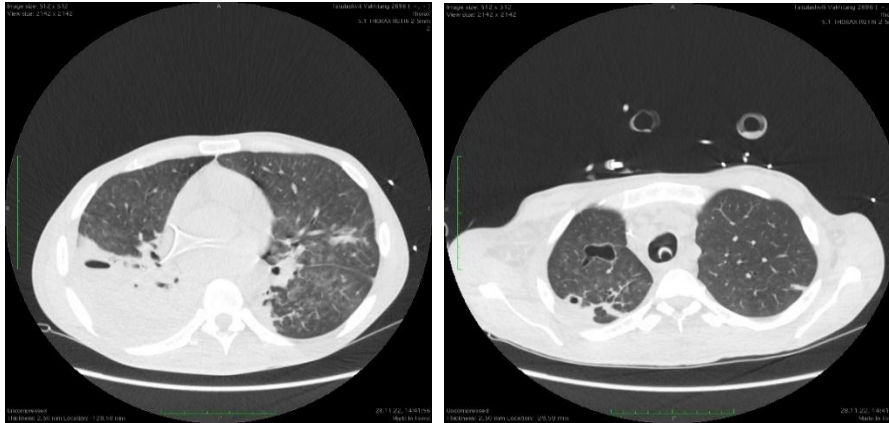
The patient was performed tracheostomy



Pict.10: CT scan of the chest. with contrast enhancement.

A tracheostomy tube is visible in the trachea, In the lungs on both sides, there is a decrease in transparency, against the background of which there are areas of medium- and small-focal infiltration, in the lower lobe on the right there is an extensive consolidation against which there are cavities with an air and small volume of liquid. In the upper lobe there are cavities with air of central

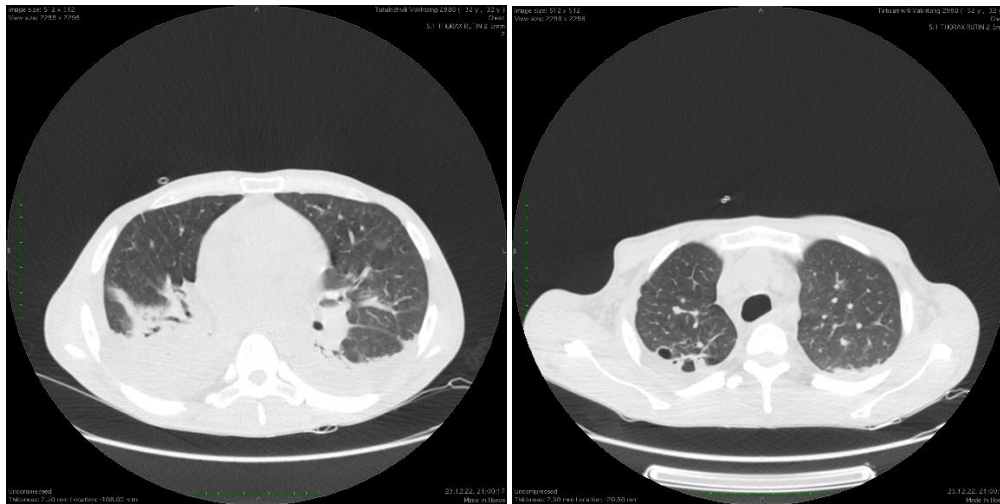
localization. On the left, there are consolidation at the level of the basal segments.(28/11/2022—pict.11)



Pict 11: CT scan of the chest.

The decrease in transparency in bilateral lungs is less pronounced. The consolidation in the lower lobe on the right is somewhat reduced, the number of air cavities against the background of the consolidation is reduced, a subpleural air cavity is preserved at its upper edge. Air

cavities in the upper lobe are no longer visible, fibrous stretch marks appear instead. There is a small fluid effusion in the bilateral pleural cavity, the maximum separation is 2.2 cm on the right and 1.5 cm on the left, no gas is detected in the bilateral pleural cavity.



Pict 12: CT scan of the chest.

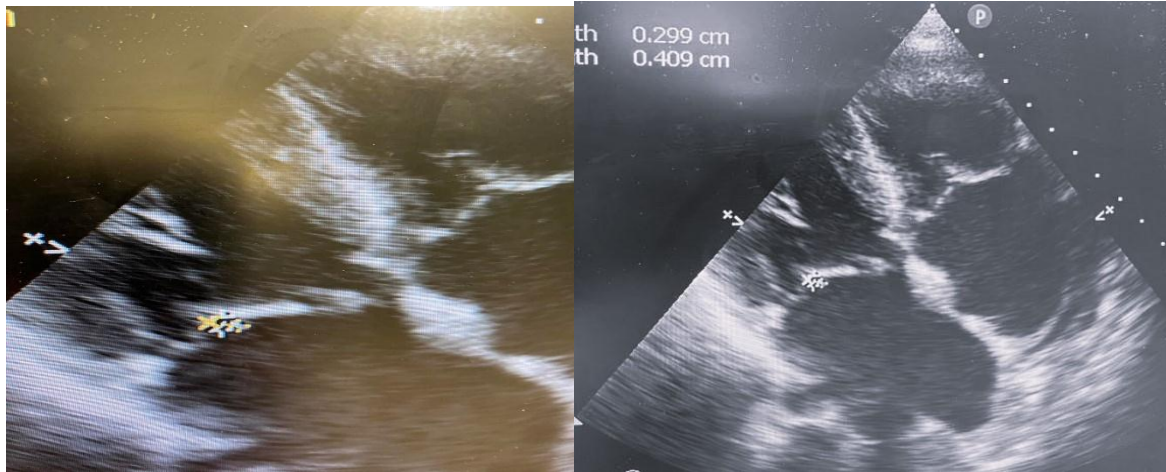
During the course of the disease, different materials were examined, different groups of microbes and different sensitivity to antibiotics were observed (table 4).

Table 4.

Bacteriological analyses	Sputem /	Blood/	Wound/
09. 10. 22	St. aureus(MRSA)/ TEicoplanin, vancomycin , tige cycline, moxifloxacin	St. aureus(MRSA)/ Vancomycin, clindamycine, Teicoplanin	St. aureus(MRSA)/ TEicoplanin, vancomycin , tige cycline, moxifloxacin, erythromycin
17. 10. 22	St aureus / (TEicoplanin, vancomycin, tige cycline, moxifloxacin) Candida spp		
24. 11. 22	KLepsiella pneumonia/ (zavicefta, gentamicin, tige cyclin)	St. aureus/MRSA	
27. 11. 22	KLepsiella pneumonia		
07. 11. 22	pseudomonas aeruginosa / (colistin -fosfomycin)		
18. 11. 22	pseudomonas aeruginosa /		

	(colistin -fosfomycin)		
04. 12. 22	pseudomonas aeruginosa / (colistin)		
19. 12. 22	KLLebsiella pneumonia// pseudomonas aeruginosa / colistin, meropenem, tgecyclin		sterile
07. 12. 22		negative	

Heart valves were evaluated periodically. After one episode of fever, the presence of vegetation on the mitral valve leaflet was revealed.



CDI, *Clostridium difficile* infections presenting with fever, abdominal pain, and diarrhea for several days and

was complicated with toxic megacolon, with unstable hemodynamic status, with septic shock.

Table 5.

Clostridium defficile	CDH,A toxin, B toxin
29.11	Negative
20.12	Positive

The scheme of antibacterial treatment implied the impact primarily on the gram-positive flora. Changing the

combination of antibiotics occurred as clinical, radiological, or laboratory parameters worsened.

09/10	10/10	13/x	19/x-20/x	23/x-08/XI	09//XI—24/XI	25/XI -- 06/XII	07/XII-19/XII	19/XII-24/XII
Pip/tazo	meropenem	meronem	meronem	meronem	meropenem	Tigecyclin	Tigecyclin	Colomycin
vancomycin	vancomycin	aciclovir	aciclovir	aciclovir	vancomycin	Zavicefta	Vancomycin	Vancomycin
			vancomicin	Vancomicin	kolomycin	Colomycin	Colomycin	Tigecyclin
			Colistin	linezolid	fosfomycin	Vancomycin	Meropenem	Meropenem
			Moxifloxacin	Moxifloxacin	Moxiflocacin	Meropenem	Metronidazol	
			fluconazol	meronem				
			meropenem	Fluconazole				

In severely critically ill patients, empiric antibiotic treatment is usually a combination of antibiotics to increase the likelihood that the bacteria causing the infection will be reliably suppressed and adequate antimicrobial therapy will not be delayed. As already mentioned, inadequate antibiotic therapy is associated with high mortality. Potential causative agents may be enterobacteria, producing ESBL, gram-negative rods resistant to carbapenems (enterobacteria, Pseudomonas, acineto bacteria).

Methicillin-resistant Staphylococcus aureus (MRSA), has also been found in blood, in sputum and in the wound. Tigecycline improved the treatment regimen for ESBL and carbapenem-resistant gram-negative rods, as well as for a number of multidrug-resistant gram-positive pathogens (MRSA, VRSA, VRE).

With the appointment of Zavicefta (ceftazidime/avibactam), the regimen was strengthened for ESBL, carbapenem-resistant gram-negative

organisms, and to expand coverage of multidrug-resistant strains of *Pseudomonas*.

A systematic review and meta-analysis of three cohort or case-control studies evaluated patients and found a lower mortality rate with DCT (dual carbapenem therapy) when compared to the control treatment (colistin, tigecycline and aminoglycoside monotherapies, or combined regimens). Synergistic drug therapy combinations that include penicillin plus cephalosporins, as well as carbapenems plus cephalosporins, have been shown to decrease the microbial counts and improve clinical outcomes in infections caused by Gram-positive bacteria. Against multidrug-resistant Gram-negative microorganisms, the use of therapeutic regimens combining beta-lactam/beta-lactam inhibitors with carbapenems has resulted in the resolution of bacterial infections. Antimicrobial resistance associated increase in mortality. Beta-lactams have a safe profile and are bactericidal against most Gram-positive and Gram-negative microorganisms. It is used of dual beta-lactam therapy to overcome multidrug-resistant pathogens, Long-course (>18 days)therapy has the obvious benefit of maximizing the chance of infection resolution. Patient discharged from hospital, with spontaneous breathing, stable parameters.

REFERENCES

- Kuehl R, Morata L, Boeing C, Subirana I, Seifert H, Rieg S, et al. Defining persistent *Staphylococcus aureus* bacteraemia: secondary analysis of a prospective cohort study. *Lancet Infect Dis*, 2020; 20: 1409–17. 10.1016/S1473-3099(20)30447-3 [PubMed] [CrossRef] [Google Scholar]
- Lesens O, Hansmann Y, Brannigan E, Remy V, Hopkins S, Martinot M, et al. Positive surveillance blood culture is a predictive factor for secondary metastatic infection in patients with *Staphylococcus aureus* bacteraemia. *J Infect*, 2004; 48: 245–52. 10.1016/j.jinf.2003.10.010 [PubMed] [CrossRef] [Google Scholar]
- Miller JM, Binnicker MJ, Campbell S, Carroll KC, Chapin KC, Gilligan PH, et al. A guide to utilization of the microbiology laboratory for diagnosis of infectious diseases: 2018 update by the Infectious Diseases Society of America and the American Society for Microbiology. *Clin Infect Dis*, 2018; 67: e1–94. 10.1093/cid/ciy381 [PMC free article] [PubMed] [CrossRef] [Google Scholar]
- Seifert H, Abele-Horn M, Fätkenheuer G, Glück T, Jansen B, Kern WV, et al. *Blutkulturdiagnostik: Sepsis, Endokarditis, Katheterinfektionen, Teil II*. München: Elsevier Urban & Fischer, 2007; 59–126. [Google Scholar]
- Meybohm P, Kleinerüschkamp A, Zacharowski K. Patient blood management. In: Rossaint R, Werner C, Zwißler B, editors. *Die Anästhesiologie*. Berlin, Heidelberg: Springer Berlin Heidelberg, 2019; 211–5. [Google Scholar]
- Weis S, Kesselmeier M, Davis JS, Morris AM, Lee S, Scherag A, et al. Cefazolin versus anti-staphylococcal penicillins for the treatment of patients with *Staphylococcus aureus* bacteraemia. *Clin Microbiol Infect*, 2019; 25: 818–27. 10.1016/j.cmi.2019.03.010 [PubMed] [CrossRef] [Google Scholar]
- Paul M, Zemer-Wassercug N, Talker O, Lishtzinsky Y, Lev B, Samra Z, et al. Are all beta-lactams similarly effective in the treatment of methicillin-sensitive *Staphylococcus aureus* bacteraemia? *Clin Microbiol Infect*, 2011; 17: 1581–6. 10.1111/j.1469-0691.2010.03425.x [PubMed] [CrossRef] [Google Scholar]
- Castells M, Khan DA, Phillips EJ. Penicillin allergy. *N Engl J Med*, 2019; 381: 2338–51. 10.1056/NEJMr1807761 [PubMed] [CrossRef] [Google Scholar]
- Liu C, Bayer A, Cosgrove SE, Daum RS, Fridkin SK, Gorwitz RJ, et al. Clinical practice guidelines by the Infectious Diseases Society of America for the treatment of methicillin-resistant *Staphylococcus aureus* infections in adults and children. *Clin Infect Dis*, 2011; 52: e18–55. 10.1093/cid/ciq146 [PubMed] [CrossRef] [Google Scholar]
- Kullar R, Davis SL, Levine DP, Rybak MJ. Impact of vancomycin exposure on outcomes in patients with methicillin-resistant *Staphylococcus aureus* bacteremia: support for consensus guidelines suggested targets. *Clin Infect Dis*, 2011; 52: 975–81. 10.1093/cid/cir124 [PubMed] [CrossRef] [Google Scholar]
- Forstner C, Dungal C, Tobudic S, Mitteregger D, Lagler H, Burgmann H. Predictors of clinical and microbiological treatment failure in patients with methicillin-resistant *Staphylococcus aureus* (MRSA) bacteraemia: a retrospective cohort study in a region with low MRSA prevalence. *Clin Microbiol Infect*, 2013; 19: E291–7. 10.1111/1469-0691.12169 [PubMed] [CrossRef] [Google Scholar]
- Soriano A, Marco F, Martínez JA, Pisos E, Almela M, Dimova VP, et al. Influence of vancomycin minimum inhibitory concentration on the treatment of methicillin-resistant *Staphylococcus aureus* bacteremia. *Clin Infect Dis*, 2008; 46: 193–200. 10.1086/524667 [PubMed] [CrossRef] [Google Scholar]
- Howden BP, Ward PB, Charles PG, Korman TM, Fuller A, Du Cros P, et al. Treatment outcomes for serious infections caused by methicillin-resistant *Staphylococcus aureus* with reduced vancomycin susceptibility. *Clin Infect Dis*, 2004; 38: 521–8. 10.1086/381202 [PubMed] [CrossRef] [Google Scholar]
- Tenover FC, Moellering RC. The rationale for revising the Clinical and Laboratory Standards Institute vancomycin minimal inhibitory concentration interpretive criteria for *Staphylococcus aureus*. *Clin Infect Dis*, 2007; 44:

- 1208–15. 10.1086/513203 [PubMed] [CrossRef] [Google Scholar]
15. Minejima E, Mai N, Bui N, Mert M, Mack WJ, She RC, et al.. Defining the breakpoint duration of *Staphylococcus aureus* bacteremia predictive of poor outcomes. *Clin Infect Dis*, 2020; 70: 566–73. 10.1093/cid/ciz257 [PMC free article] [PubMed] [CrossRef] [Google Scholar]
16. Shariati A, Dadashi M, Moghadam MT, van Belkum A, Yaslianifard S, Darban-Sarokhalil D. Global prevalence and distribution of vancomycin resistant, vancomycin intermediate and heterogeneously vancomycin intermediate *Staphylococcus aureus* clinical isolates: a systematic review and meta-analysis. *Sci Rep*, 2020; 10: 12689. 10.1038/s41598-020-69058-z [PMC free article] [PubMed] [CrossRef] [Google Scholar]
17. Moise PA, North D, Steenbergen JN, Sakoulas G. Susceptibility relationship between vancomycin and daptomycin in *Staphylococcus aureus*: facts and assumptions. *Lancet Infect Dis*, 2009; 9: 617–24. 10.1016/S1473-3099(09)70200-2 [PubMed] [CrossRef] [Google Scholar]
18. Prasad P, Sun J, Danner RL, Natanson C. Excess deaths associated with tigecycline after approval based on noninferiority trials. *Clin Infect Dis*, 2012; 54: 1699–709. 10.1093/cid/cis270 [PMC free article] [PubMed] [CrossRef] [Google Scholar]
19. White BP, Barber KE, Stover KR. Ceftaroline for the treatment of methicillin-resistant *Staphylococcus aureus* bacteremia. *Am J Health Syst Pharm*, 2017; 74: 201–8. 10.2146/ajhp160006 [PubMed] [CrossRef] [Google Scholar]
20. Bryson-Cahn C, Beiler AM, Chan JD, Harrington RD, Dhanireddy S. Dalbavancin as secondary therapy for serious *Staphylococcus aureus* infections in a vulnerable patient population. *Open Forum Infect Dis*, 2019; 6: ofz028. 10.1093/ofid/ofz028 [PMC free article] [PubMed] [CrossRef] [Google Scholar]
21. van Hise NW, Anderson M, McKinsey D, McKinsey J, Harting B, Belmares J, et al.. The use of dalbavancin for *Staphylococcus aureus* bacteremia in persons who inject drugs (PWID). *Open Forum Infect Dis*, 2019; 6: S772. 10.1093/ofid/ofz360.1933 [CrossRef] [Google Scholar]
22. Iversen K, Ihlemann N, Gill SU, Madsen T, Elming H, Jensen KT, et al.. Partial oral versus intravenous antibiotic treatment of endocarditis. *N Engl J Med*, 2019; 380: 415–24. 10.1056/NEJMoa1808312 [PubMed] [CrossRef] [Google Scholar]
23. Kaasch AJ, Fätkenheuer G, Prinz-Langenohl R, Paulus U, Hellmich M, Weiß V, et al.. Early oral switch therapy in low-risk *Staphylococcus aureus* bloodstream infection (SABATO): study protocol for a randomized controlled trial. *Trials*, 2015; 16: 450. 10.1186/s13063-015-0973-x [PMC free article] [PubMed] [CrossRef] [Google Scholar]
24. Bai AD, Showler A, Burry L, Steinberg M, Ricciuto DR, Fernandes T, et al. Impact of infectious disease consultation on quality of care, mortality, and length of stay in *Staphylococcus aureus* bacteremia: results from a large multicenter cohort study. *Clin Infect Dis*, 2015; 60: 1451–61. 10.1093/cid/civ120 [PubMed] [CrossRef] [Google Scholar]
25. Kaasch AJ, Fowler VG, Rieg S, Peyerl-Hoffmann G, Birkholz H, Hellmich M, et al. Use of a simple criteria set for guiding echocardiography in nosocomial *Staphylococcus aureus* bacteremia. *Clin Infect Dis*, 2011; 53: 1–9. 10.1093/cid/cir320 [PMC free article] [PubMed] [CrossRef] [Google Scholar]
26. Tubiana S, Duval X, Alla F, Selton-Suty C, Tattevin P, Delahaye F, et al.. The VIRSTA score, a prediction score to estimate risk of infective endocarditis and determine priority for echocardiography in patients with *Staphylococcus aureus* bacteremia. *J Infect*, 2016; 72: 544–53. 10.1016/j.jinf.2016.02.003 [PubMed] [CrossRef] [Google Scholar]
27. Salvador VB, Chapagain B, Joshi A, Brennessel DJ. Clinical risk factors for infective endocarditis in *Staphylococcus aureus* bacteremia. *Tex Heart Inst J*, 2017; 44: 10–5. 10.14503/THIJ-15-5359 [PMC free article] [PubMed] [CrossRef] [Google Scholar]
28. Oever J ten, Jansen JL, van der Vaart TW, Schouten JA, Hulscher ME, Verbon A. Development of quality indicators for the management of *Staphylococcus aureus* bacteraemia. *J Antimicrob Chemother*, 2019; 74: 3344–51. 10.1093/jac/dkz342 [PMC free article] [PubMed] [CrossRef] [Google Scholar]
29. Tong SY, Lee TC. *Staphylococcus aureus* bacteraemia: does duration matter? *Lancet Infect Dis*, 2020; 20: 1353–4. 10.1016/S1473-3099(20)30590-9 [PubMed] [CrossRef] [Google Scholar]
30. Rieg S, Ernst A, Peyerl-Hoffmann G, Joost I, Camp J, Hellmich M, et al. Combination therapy with rifampicin or fosfomycin in patients with *Staphylococcus aureus* bloodstream infection at high risk for complications or relapse: results of a large prospective observational cohort. *J Antimicrob Chemother*, 2020; 75: 2282–90. 10.1093/jac/dkaa144 [PubMed] [CrossRef] [Google Scholar]
31. Rieg S, Joost I, Weiß V, Peyerl-Hoffmann G, Schneider C, Hellmich M, et al. Combination antimicrobial therapy in patients with *Staphylococcus aureus* bacteraemia—a post hoc analysis in 964 prospectively evaluated patients. *Clin Microbiol Infect*, 2017; 23: 406.e1–e8. 10.1016/j.cmi.2016.08.026 [PubMed] [CrossRef] [Google Scholar]
32. Karlsen Ø, Borgen P, Bragnes B, Figved W, Grøgaard B, Rydinge J, et al. Rifampin combination therapy in staphylococcal prosthetic joint infections: a randomized controlled trial. *J Orthop Surg Res*,

- 2020; 15: 365. 10.21203/rs.2.23809/v1 [PMC free article] [PubMed] [CrossRef] [Google Scholar]
33. Cheng MP, Lawandi A, Butler-Laporte G, de l'Etoile-Morel S, Paquette K, Lee TC. Adjunctive daptomycin in the treatment of methicillin-susceptible *Staphylococcus aureus* bacteremia: a randomized controlled trial. *Clin Infect Dis*, 2020; 10: 1093/cid/ciaa1000. [Epub ahead of print]. [PubMed] [CrossRef] [Google Scholar]
34. Tong SY, Lye DC, Yahav D, Sud A, Robinson JO, Nelson J, et al.. Effect of vancomycin or daptomycin with vs without an antistaphylococcal β -lactam on mortality, bacteremia, relapse, or treatment failure in patients with MRSA bacteremia: a randomized clinical trial. *JAMA*, 2020; 323: 527–37. 10.1001/jama.2020.0103 [PMC free article] [PubMed] [CrossRef] [Google Scholar]
35. Hagel S, Gantner J, Spreckelsen C, Fischer C, Ammon D, Saleh K, et al.. Hospital-wide EElectronic medical record evaluated computerised decision support system to improve outcomes of patients with staphylococcal bloodstream infection (HELP): study protocol for a multicentre stepped-wedge cluster randomised trial. *BMJ Open*, 2020; 10: e033391. 10.1136/bmjopen-2019-033391 [PMC free article] [PubMed] [CrossRef] [Google Scholar]
36. Thwaites GE, Scarborough M, Szubert A, Nsutebu E, Tilley R, Greig J, et al.. Adjunctive rifampicin for *Staphylococcus aureus* bacteraemia (ARREST): a multicentre, randomised, double-blind, placebo-controlled trial. *Lancet*, 2018; 391: 668–78. 10.1016/S0140-6736(17)32456-X [PMC free article] [PubMed] [CrossRef] [Google Scholar]
37. Management of *Staphylococcus aureus* Bloodstream Infections, Aurelia Kimmig,¹ Stefan Hagel,¹ Sebastian Weis,^{1,2,3} Christina Bahrs,^{1,4} Bettina Löffler,⁵ and Mathias W. Pletz^{1,*} *Front Med (Lausanne)*. 2020; 7: 616524. Published online 2021 Mar 5. doi: REVIEW article.
38. Multidrug-resistant, extensively drug-resistant and pandrug-resistant bacteria: an international expert proposal for interim standard definitions for acquired resistance ,A-P Magiorakos¹, A Srinivasan, R B Carey, Y Carmeli, M E Falagas, C G Giske, S Harbarth, J F Hindler, G Kahlmeter, B Olsson-Liljequist, D L Paterson, L B Rice, J Stelling, M J Struelens, A Vatopoulos, J T Weber, D L Monnet, 2012 Mar; 18(3): 268-81. doi: 10.1111/j.1469-0691.2011.03570.x. Epub 2011 Jul 27. *Clin Microbiol Infect*
39. The threat of multidrug-resistant/extensively drug-resistant Gram-negative respiratory infections: another pandemic, Daniel Reynolds, Jason P. Burnham, Cristina Vazquez Guillamet, Mikaela McCabe, Valerie Yuenger, Kevin Betthausen, Scott T. Micek, Marin H. Kollef. *European Respiratory Review*, 2022; 31: 220068. DOI: 10.1183/16000617.0068-2022.