

POST-CALDWELL-LUC MUCOCELES IN MAXILLARY SINUS

Dr. Alisha Alex Kollareth*

88/1, Sidhivinayak bungalows, Near Pushpam 2 bungalows, Sahajanand complex lane, Kabir Enclave road, Ghuma, Ahmedabad, Gujarat, India.

Received date: 29 March 2021

Revised date: 19 April 2021

Accepted date: 09 May 2021

*Corresponding author: Dr. Alisha Alex Kollareth

88/1, Sidhivinayak bungalows, Near Pushpam 2 bungalows, Sahajanand complex lane, Kabir Enclave road, Ghuma, Ahmedabad, Gujarat, India.

ABSTRACT

Transnasal inferior meatal antrostomy is increasingly used for the treatment of post-Caldwell–Luc mucocoeles in maxillary sinus. This study aimed to report the outcomes after inferior meatal antrostomy with a mucosal flap for recurrent mucocoeles. **Method:** The records of patients who had undergone transnasal inferior meatal antrostomy with or without a mucosal flap were reviewed. **Results:** Transnasal endoscopic inferior meatal antrostomy with or without a mucosal flap was performed in 21 and 49 patients, respectively. No complications were observed. A closing of the antrostomy was found in 9 (18.4 percent) of the 49 patients who underwent antrostomy without a mucosal flap. No closings were observed in the 21 patients who underwent antrostomy with a mucosal flap. There was a significant difference in the rate of closing for surgery with and without the mucosal flap. **Conclusion:** Transnasal endoscopic inferior meatal antrostomy with a mucosal flap is a safe method for the treatment of post-Caldwell–Luc maxillary mucocoeles that effectively prevents recurrence.

INTRODUCTION

A mucocele, which may contain mucoid or mucopurulent fluid, is a benign cystic disorder. Post-Caldwell–Luc maxillary mucocoeles originate from within the maxillary sinus. If they expand because of an increase in their fluid content, they may affect the orbit through erosion, and bone destruction may eventually occur. Clinical symptoms associated with maxillary mucocoeles include cheek bulging, cheek pain, dental problems, diplopia, orbital pain and vision loss.^[1] Surgery is considered necessary to effectively treat a post-Caldwell–Luc maxillary mucocele. Post-Caldwell–Luc maxillary mucocoeles were previously treated by performing the Caldwell–Luc operation; recently, through, transnasal endoscopic surgery a middle and/or inferior meatal approach has been used.^[2–7] The inferior meatal approach is recommended as the surgical technique of choice.⁶ However, the recurrence of sinus mucocoeles has been reported.^[2–4] For example, Devars du Mayne et al.^[2] reported that 23.5 per cent of the patients who underwent surgery for sinus mucocoeles developed recurrence after a mean interval of four years. Mucosal flaps have been used in dacryocystorhinostomy to prevent the opening from closing and the recurrence of obstruction.^[8–11] Durr and Goldberg^[12] also used endoscopic partial medial maxillectomy with a mucosal

flap to treat five maxillary sinus mucocoeles in four patients. Nevertheless, a detailed survey of the usefulness of the mucosal flap, and particularly of inferior meatal antrostomy with a mucosal flap, in preventing recurrence has not been performed for maxillary mucocoeles. Therefore, we examined the post-operative outcomes in patients who underwent transnasal endoscopic inferior meatal antrostomy with or without a mucosal flap, and compared the efficacy and safety of the two procedures.

METHOD

Surgical Approach - Inferior meatal antrostomy was performed using the transnasal endoscopic approach, with preservation of the inferior turbinate (Figure 1). To this end, the inferior turbinate was pushed medially, to allow better access to the inferior meatus and its lateral wall in all patients. An incision was made into the lateral wall of the inferior meatus (Figure 1a), and the lateral nasal mucosa was exfoliated with a suction elevator in patients with a mucosal flap (Figure 1b). The top and bottom of the mucosal flap were cut (Figure 1c and d), and the mucosal flap was prepared. In patients without a mucosal flap, the lateral wall mucosa of the inferior meatus was removed without preparation of the mucosal flap.

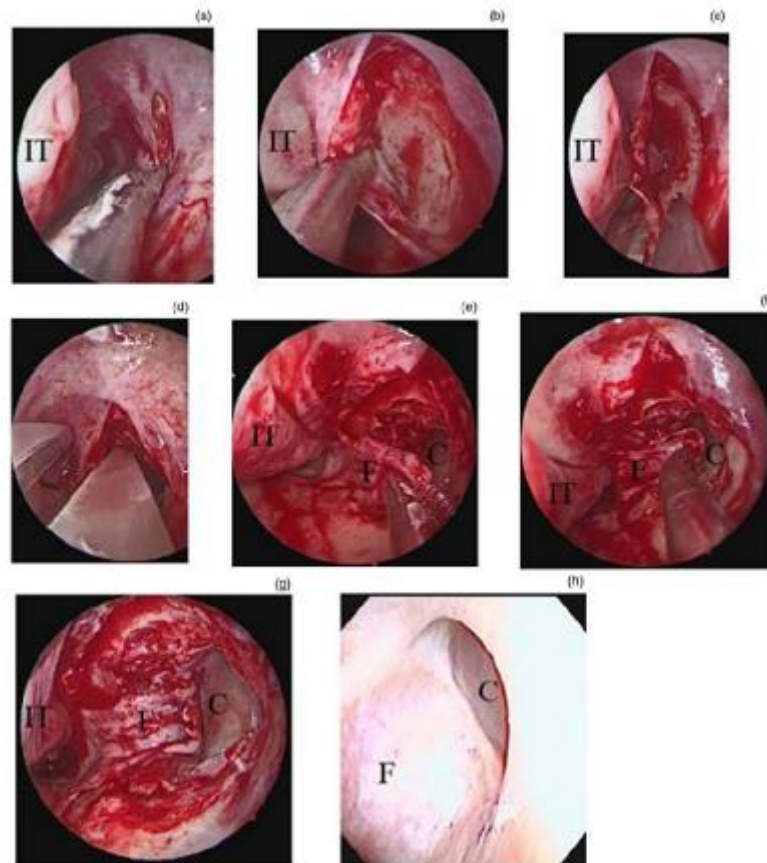


Fig. 1. Preparation of the mucosal flap for the left maxillary mucocele during the surgery and view after the surgery. (a) Incision into the lateral wall of the inferior meatus. (b) Exfoliation of the mucosal flap off the lateral nasal wall of the inferior meatus. (c) Cutting of the bottom of the mucosal flap. (d) Cutting of the top of the mucosal flap. (e) Mucosal flap. (f) Rotation of the mucosal flap. (g) Mucosal flap, which covers the bone of the posterior edge of the opening. (h) Endoscopic view of the opening into the maxillary sinus after the surgery. IT = inferior turbinate; F = flap; C = cyst

Osteotomy of the medial maxillary wall was performed. Following the confirmation of a mucocele, an incision was made into the wall of the cyst to first drain the contents before the opening was enlarged. Any damage to the nasolacrimal duct was carefully avoided during this process. In the last step of the procedure, the bone at the posterior edge of the opening was covered with the mucosal flap in patients with a mucosal flap (Figure 1e–g). Surgery with the mucosal flap was performed only in patients who consented to undergo such a procedure. Patients who did not consent to undergo surgery with the mucosal flap underwent the endoscopic inferior meatal antrostomy without the mucosal flap. This retrospective study comprised patients who underwent endoscopic inferior meatal antrostomy for the treatment of recurrent post-Caldwell–Luc mucoceles in the maxillary sinus from 1 January 2001 to 31 May 2015. Patients were included if the existence of the opening to the maxillary sinus mucoceles could be evaluated with a fibrescope or computed tomography (CT) scan within three to five years after inferior meatal antrostomy (Figures 1h and 2). In all cases, the fibrescope procedure was performed for the first time. A CT scan was performed in all cases when the opening was not identified with the fibrescope.

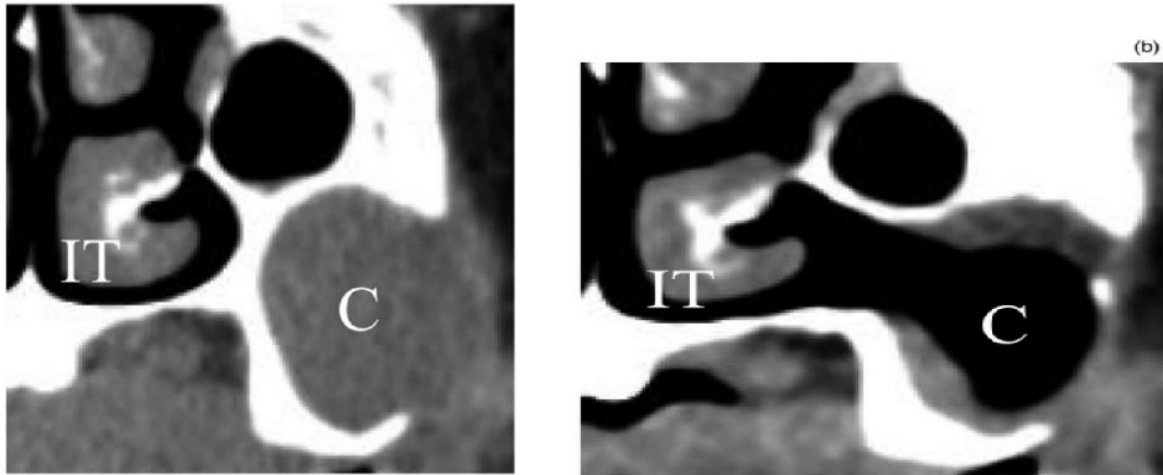


Fig. 2. Computed tomography scan (a) before and (b) after inferior meatal antrostomy with a mucosal flap, in patients with a maxillary mucocele. IT = inferior turbinate; C = cyst

This study was approved by the Nagoya City University Ethical Committee.

STATISTICAL ANALYSIS

A statistical comparison of the outcomes obtained for surgery with or without the mucosal flap and sex was performed using chi-square tests. A statistical comparison of results between the two groups was performed using the Mann–Whitney U test for age, diameter and follow-up duration. A statistically significant difference was defined as $p < 0.05$.

RESULTS

Patients' demographics - Seventy patients who underwent inferior meatal antrostomy for the treatment of recurrent post-Caldwell–Luc maxillary mucoceles were included in this study. All patients had undergone a Caldwell–Luc operation more than 15 years previously for the treatment of sinusitis. Transnasal endoscopic inferior meatal antrostomy without a mucosal flap was performed in 49 patients (26 males and 23 females); the mean age at surgery was 64.5 years (range of 55–82 years). 21 patients (10 males and 11 females) underwent transnasal endoscopic inferior meatal antrostomy with a mucosal flap; the mean age at surgery was 64.3 years (range of 56–80 years). There was no statistically significant difference between the two groups with respect to age and sex.

COMPARISON OF SURGERY WITH OR WITHOUT MUCOSAL FLAP

The presence of an opening to the maxillary sinus mucoceles was examined with either a fibroscope or CT within three to five years after surgery. The mean follow-up duration was 47.2 months (range of 37–59 months) for patients who had undergone surgery without a mucosal flap, and 48.4 months (range of 38–56 months) for patients who had undergone surgery with a mucosal

flap. There was no statistically significant difference in the follow-up duration between the two groups. The antero-posterior, lateral and longitudinal diameters of the maxillary cysts were measured using CT. The maximum antero-posterior diameters of patients who underwent surgery with or without a mucosal flap were 3.3 ± 0.2 cm and 3.2 ± 0.1 cm, respectively. The maximum lateral diameters of patients with or without a mucosal flap were 3.7 ± 0.3 cm and 3.4 ± 0.1 cm, respectively. The maximum longitudinal diameters of patients with or without a mucosal flap were 3.4 ± 0.2 cm and 3.2 ± 0.1 cm, respectively. There were no significant differences between the two groups with respect to the antero-posterior, lateral or longitudinal diameters of cysts. A closing of the inferior meatal antrostomy was observed in 9 (18.4 per cent) of the 49 patients who had undergone transnasal endoscopic inferior meatal antrostomy without a mucosal flap. Patency of the inferior meatal antrostomy was confirmed in all 21 patients who had undergone the procedure with a mucosal flap. There was a statistically significant difference in the rate of closing between the group with and the group without a mucosal flap ($p < 0.05$; Table 1).

COMPLICATIONS ASSOCIATED WITH THE SURGERY

No intra-operative or post-operative complications were observed in the 70 patients with recurrent maxillary sinus mucoceles. The nasolacrimal duct and inferior turbinate were preserved in all patient.

DISCUSSION

In this study, we followed up 70 patients who had undergone inferior meatal antrostomy with or without a mucosal flap for recurrent maxillary sinus mucoceles after a Caldwell–Luc operation. No intra-operative or post-operative complications were observed.

Table 1. Relationship between mucosal flap and recurrence

Mucosal flap presence	No recurrence	Recurrence
No mucosal flap	40	9
Mucosal flap	21	0

Data represent numbers of patients

This suggests that inferior meatal antrostomy with or without a mucosal flap is a safe procedure. No closings of the antrostomy were observed in the 21 patients who had undergone inferior meatal antrostomy with a mucosal flap. The rate of closing in patients who underwent the procedure with the mucosal flap was significantly lower than that in patients who underwent the procedure without the mucosal flap. These results suggest that a mucosal flap prevents the opening from closing, thereby reducing the recurrence rate of maxillary sinus mucocoeles. Thus, inferior meatal antrostomy with a mucosal flap may be an effective strategy for the treatment of maxillary sinus mucocoeles.

Several surgical techniques have been developed to prevent the recurrence of maxillary mucocoeles. For example, Ono et al.^[13] used a T-tube stent to prevent recurrence. However, a stent might need to be removed; as it is a foreign body, it may cause problems such as infection. In contrast, a mucosal flap is made of autologous material and removal is not needed, which is an additional advantage of using mucosal flaps. Devars du Mayne et al.² reported that 16 (23.5 per cent) of 68 patients developed recurrence after surgery for sinus mucocoeles. Makeieff et al.⁴ reported that one (12.5 per cent) out of eight maxillary sinuses with mucocoeles that were treated endoscopically developed a recurrence, and one (50 per cent) of two sinuses that were treated by a classical external approach (Caldwell–Luc operation) developed a recurrence. Huang et al.³ observed recurrence in 5 (14.9 per cent) out of 34 maxillary mucocoeles after transnasal endoscopic surgery. In contrast, other studies have reported no recurrences after surgery for maxillary sinus mucocoeles.^{5–7} To our knowledge, no studies have, to date, reported on the recurrence rate after the second surgery in only patients with recurrent maxillary sinus mucocoeles. The present study showed that the rate of closing of antrostomy was 18.4 per cent after inferior meatal antrostomy without a mucosal flap in patients with recurrent maxillary mucocoeles. Durr and Goldberg¹² performed partial medial maxillectomy with a mucosal flap for maxillary sinus mucocoeles, and conducted partial resection of the anterior inferior turbinate to obtain adequate access to the lateral nasal wall of the inferior meatus. Our method, as described here, does not involve resection of the inferior turbinate, but forceps were used to push the

inferior turbinate medially. Our results indicate that inferior meatal antrostomy without resection of the inferior turbinate may be used to successfully treat maxillary sinus mucocoeles. Further, while Durr and Goldberg¹² covered the floor of the nose and the inferior bony border during maxillectomy with the mucosal flap, we used a technique in which only the bone at the posterior edge of the opening into the mucocoele was covered with the mucosal flap. Thus, there is a difference between these techniques. However, it is not known whether this accounts for the difference in outcomes.

Further studies are needed to address this question.

- Recently, transnasal inferior meatal antrostomy has been used for treating post-Caldwell–Luc mucocoeles in the maxillary sinus.
- Maxillary sinus mucocoele recurrence has been reported after surgery.
- Transnasal inferior meatal antrostomy, with or without a mucosal flap, is a safe method.
- Transnasal inferior meatal antrostomy with a mucosal flap is effective at preventing antrostomy closing.

REFERENCES

- 1 Simoes JC, Nogueira-Neto FB, Gregorio LL, Caparroz Fde A, Kosugi EM. Visual loss: a rare complication of maxillary sinus mucocoele. *Braz J Otorhinolaryngol*, 2015; 81: 451–3.
- 2 Devars du Mayne M, Moya-Plana A, Malinvaud D, Laccourreye O, Bonfils P. Sinus mucocoele: natural history and long-term recurrence rate. *Eur Ann Otorhinolaryngol Head Neck Dis*, 2012; 129: 125–30.
- 3 Huang CC, Chen CW, Lee TJ, Chang PH, Chen YW, Chen YL et al. Transnasal endoscopic marsupialization of postoperative maxillary mucocoeles: middle meatal antrostomy versus inferior meatal antrostomy. *Eur Arch Otorhinolaryngol*, 2011; 268: 1583–7.
- 4 Makeieff M, Gardiner Q, Mondain M, Crampette L. Maxillary sinus mucocoeles—10 cases--8 treated endoscopically. *Rhinology*, 1998; 36: 192–5.
- 5 Caylakli F, Yavuz H, Cagici AC, Ozluoglu LN. Endoscopic sinus surgery for maxillary sinus mucocoeles. *Head Face Med*, 2006; 2: 29.

- 6 Lee JY, Baek BJ, Byun JY, Shin JM. Long-term efficacy of inferior meatal antrostomy for treatment of postoperative maxillary mucocoeles. *Am J Otolaryngol*, 2014; 35: 727–30.
- 7 Albu S, Dutu AG. Concurrent middle and inferior meatus antrostomy for the treatment of maxillary mucocoeles. *Clujul Med*, 2017; 90: 392–5.
- 8 Elwan S. A randomized study comparing DCR with and without excision of the posterior mucosal flap. *Orbit*, 2003; 22: 7–13.
- 9 Sham CL, van Hasselt CA. Endoscopic terminal dacryocystorhinostomy. *Laryngoscope*, 2000; 110: 1045–9.
- 10 Wormald PJ. Powered endoscopic dacryocystorhinostomy. *Laryngoscope*, 2002; 112: 69–72.
- 11 Mueller SK, Freitag SK, Lefebvre DR, Bleier BS. Endoscopic DCR using bipediced interlacing mucosal flaps. *Laryngoscope*, 2018; 128: 794–7.
- 12 Durr ML, Goldberg AN. Endoscopic partial medial maxillectomy with mucosal flap for maxillary sinus mucocoeles. *Am J Otolaryngol*, 2014; 35: 115–19.
- 13 Ono N, Ito S, Homma H, Okada H, Murata J, Ikeda K. Endoscopic endonasal management of recurrent maxillary mucocoeles using biliary T-tube stenting. *Ear Nose Throat J*, 2017; 96: 469–76.