

DOPAMINE AGONIST RESPONSIVE ABULIA: A CASE REPORT AND LITERATURE REVIEW

Hakan Şilek*, Ayça Serap TUNCER, Bahar Erbaş

Bulgurlu Mah Karlıdere Cad Toygar Sâ°Tesâ° 20/4 Ācskâcedar City: Ā°Stanbul.

Received date: 20 March 2020

Revised date: 10 April 2020

Accepted date: 30 April 2020

*Corresponding author: Hakan Şilek

Bulgurlu Mah Karlıdere Cad Toygar Sâ°Tesâ° 20/4 Ācskâcedar City: Ā°Stanbul.

ABSTRACT

Abulia is a "syndrome of hypofunction," characterized by apathy, slowness of thought (bradyphrenia), blunting of emotional responses and response to external stimuli decreased or complete lack of initiative, spontaneity and drive. We describe a case of a socially active 73-year-old male patient who presented with symptoms of abulia which may have occurred due to damage of the frontosubcortical circuits following an cardiac mitral valve replacement. The patient's symptoms improved dramatically following treatment with pramipexole.

KEYWORDS: Abulia, acute ischemia, nucleus caudatus lesion, dopamine agonist treatment.

BACKGROUND

Abulia is supposed to occur because of a malfunction of dopamine-dependent circuitry of brain. Lesions anywhere in the "centro-medial core" of brain frontal-subcortical circuitry, from frontal lobes to the brainstem, may produce this condition.^[1] We report a 73 year old right handed male patient that was referred by cardiovascular surgeon. Our case was evaluated on the third day post-op in the cardiovascular surgery service and his main complaints were forgetfulness, urinary and fecal incontinence. Speech pattern was slow and due to apraxia without difficulty in swallowing he was fed with the support of his relatives. On neurologic examination cognitive dementia findings, ideomotor apraxia and abulia. In cranial magnetic resonance image (MRI), a few millimetric acute ischemic lesions one in left caudate nucleus and on both subcortical different locations (Figure1). Previously anticoagulant and antiaggregant therapy enoxsarin sodium 6000 anti-xa subcutaneous two doses per day and per oral acetylsalicylic acid 300 mg/day was started. In the three-week follow-up of the patient, although urinary and fecal incontinence decreased all complaints remained unchanged. Dopamine agonist treatment Pramipexole was 0.500 mg/day was started because there was no improvement in the patient's clinical complaints during this period. Significant improvement was observed on the second day of dopamine agonist treatment.

The reason that makes this case so remarkable is the unusual location of brain lesion of acute ischemia that is the cause of the patient's clinical complaints. All other complaints except for urinary and fecal incontinence complain persisted for three weeks without any resolving. Dopaminergic medical treatment was seen to be effective in Abulia.^[2] Initial dose of pramipexole was 0.500 mg/day. Two days later, more than half of the complaints were resolved and were confirmed by the patient's relatives. In the fourth week of pramipexol at a dose of 0.750 mg/day, it was observed that all of his complaints disappeared. The patient speaks fluently, his walking pattern returned to normal speed and he turned to normal cognitive functions on the clock drawing test.

These cases highlight the value of identifying that stroke induced abulia treatment with dopamine agonists may have a place in its treatment. Several medical options may be involved in the treatment of abulia, including Carbidopa / levodopa, bromocriptine and other dopamine agonists.^[3] Our case showed a fairly good response to pramipexol treatment. Pramipexole has been proven to be effective in the treatment of apathy by acting on D3 and 5-HT receptors.^[4] On follow-up, patient is asymptomatic and continuing anticoagulant treatment and pramipexole dose 0.750 mg/day.

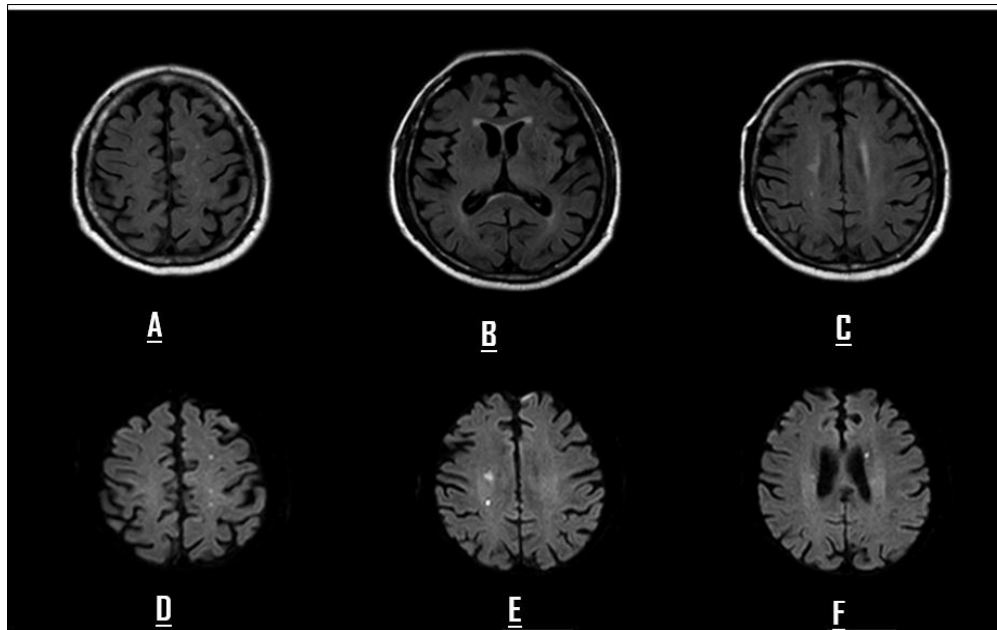


Figure 1: Brain MRI Axial plan FLAIR and DWI . In DWI images bilaterally acute ischemic lesions, on F image acute left caudate nucleus millimetric ischemic lesion.

DISCUSSION

The different part of brain frontal-subcortical circuitry lesions may be a reason for aboulia. Aboulia is most commonly associated with lesions of the anterior cingulate cortex (ACC).^[5] However, aboulia is also caused by subcortical lesions of the anterior thalamus, caudate nucleus, globus pallidus, and internal capsule.^[6] Lesions of the caudate nucleus can also cause aboulia, dementia but can rarely be a cause of apraxia.^[7] Caudate nucleus dopaminergic deficit exhibit contributions to aboulia and cognitive impairment in our case.^[8] When frontal lesions show broad frontal cortical and subcortical involvement, aboulia clinical symptoms can be expected to occur. At first glance we failed to consider that millimeter acute ischemic lesions could be the source of clinical findings, but after the literature review, we decided that aboulia clinical picture may occur as a result of the involvement of strategic areas. The most common symptoms of acute lesions of unilateral caudate nucleus are aboulia and confusion, disorientation, respectively.^[9] Behavioral change may have occurred as a result of loss of interconnectivity of striatal efferent projections from the caudate nucleus. The caudate nucleus connects associative cortex, including frontal, parietal, and temporal lobes, with deeper anatomic structures by cortico-pallido-nigra-thalamocortical loops.^[3,10]

REFERENCES

- Hastak SM, Gorawara PS, Mishra NK. Aboulia: no will, no way. *J Assoc Physicians India*. 2005 Sep;53:814-8 PMID: 16334629
- Daniel A, Drubach, Zeiligh G: Treatment of Aboulia with Carbidopa/Levodopa. *J Neur Rehab*. Vol 3 No9 1995 /doi.org/10.1177/154596839500900303
- Cohen, R.A., et al., 1999. Alteration of intention and self-initiated action associated with bilateral anterior cingulotomy. *Journal of Neuropsychiatry and Clinical Neurosciences* 11, 444–453 .
- DOI:10.1176/jnp.11.4.444
- Vijayaraghavan, L., Krishnamoorthy, E.S., Brown, R.G., Trimble, M.R., 2002. Aboulia: a Delphi survey of British neurologists and psychiatrists. *Movement Disorders: Official Journal of the Movement Disorder Society* 17, 1052–1057 doi: 10.1002/mds.10194.
- Sun-Young OH, Jung Seok Lee A case of strategic infarct dementia in left caudate nucleus: *Annals of General Psychiatry* 5 (Suppl 1):S28 2006 DOI: 10.1186/1744-859X-5-S1-S282
- Nicolaas I. Bohnen, Roger L. Albin: Frequency of Cholinergic and Caudate Nucleus Dopaminergic
- Deficits Across the Predemented Cognitive Spectrum of Parkinson Disease and Evidence of Interaction Effects. *AMA Neurol*. 2015;72(2):194-200. doi:10.1001/jamaneurol.2014.275
- Kumral E, Evyapan D, Balkir K: Acute Caudate Vascular lesions: *Stroke* 30:100-108, 1990 doi: 10.1161/01.str.30.1.100 Pramstaller P, Marsden C. The basal ganglia and apraxia: *Brain* 119:319–340, 1996 doi: 10.1093/brain/119.1.319.
- Alexander GE, DeLong MR. Microstimulation of the primate neostriatum, I: physiological properties of striatal microexcitable zones. *J Neurophysiol*. 1985;53:1417–1432. doi: 10.1152/jn.1985.53.6.1401.
- T.T.-J. Chong and M. Husain, The role of dopamine in the pathophysiology and treatment of apathy. In: Bettina Studer and Stefan Knecht, editors, *Progress in Brain Research*, Vol. 229, Amsterdam: Elsevier, 2016, pp. 389-426. <https://doi.org/10.1016/bs.pbr.2016.05.007>.